

Added Value of MDCT in Cochlear Parameters Assessment in Patients with Sensory Neural Hearing Loss Candidates for Cochlear Implantation

Yosrsa Fouad Mohammed Rashad^{1,*}, Rania Essam-El-Dein Mohamed Ali¹,
Mohammed Hisham Ali Hamad², Abdelmonem Nooman Darweesh¹

¹Department of Radio-diagnosis & Medical Imaging, Tanta University, Tanta, Egypt

²Department of Otorhinolaryngology, Tanta University, Tanta, Egypt

E-mail Address:

Dr.yosra.rashad@gmail.com (Y. F. M. Rashad)

To cite this article:

Yosrsa Fouad Mohammed Rashad, Rania Essam-El-Dein Mohamed Ali, Mohammed Hisham Ali Hamad, Abdelmonem Nooman Darweesh. Added Value of MDCT in Cochlear Parameters Assessment in Patients with Sensory Neural Hearing Loss Candidates for Cochlear Implantation. *International Journal of Medical Imaging*. Vol. 6, No. 4, 2018, pp. 33-39. doi: 10.11648/j.ijmi.20180604.11

Received: December 2, 2018; **Accepted:** December 19, 2018; **Published:** January 17, 2019

Abstract: The aim of this study is to detect the variations in cochlear size which may help in selection of the best cochlear implant electrode length and may also influence the insertion depth angles of the electrode arrays. To achieve this goal, 40 patients (21 females and 19 male) were included, their age ranged from 4 to 57 years (mean 24.63 ± 17.30 years), pre- and post-operative non-contrast CT examination of the petrous bone was performed. It showed that, the cochlear distance (diameter A) ranged between 7.10 – 10.10mm (mean 8.53 ± 0.56 mm), The cochlear duct length ranged between 25.50 – 38.0mm (mean 31.45 ± 2.33 mm), postoperative, insertion depth angles ranged between 405 to 500o (mean 450.17 ± 36.77), for advanced bionics, 211.0 – 420.0o (mean 367.56 ± 71.81 o) for cochlear nucleus, 371.0 – 520.0o (mean 456.14 ± 61.33 o) for Flex 28, and 475.0 – 598.0o (mean 513.06 ± 31.76 o) for Med-El standard electrode, a non-significant correlation was found between the insertion depth angles and the cochlear distance. A statistically significant positive correlation was found between the insertion depth angle and length of the electrode array. Therefore, it is concluded that assessing the cochlear parameters helps to choose the optimal electrode to provide proper cochlear coverage while avoiding insertional trauma.

Keywords: MDCT= Multidetector Computed Tomography, SNHL=Sensorineural Hearing Loss, CDL=Cochlear Duct Length, CD=Cochlear Distance, MPR=Multiplanar Reconstruction, IAC=Internal Auditory Canal

1. Introduction

Sensory neural hearing loss (SNHL) is the result of abnormalities of the inner ear, vestibulocochlear nerve or central auditory pathway which disturb their proper function. [1] A variety of pathologic conditions cause hearing loss in children, including genetic, environmental and infectious causes. [2].

Cochlear implantation and subsequent rehabilitation are considered as a highly effective method in children with prelingual severe SNHL who do not receive acceptable benefit from hearing aids. [3].

Multidetector computed tomography (MDCT) scanners have allowed 3D-curved multi-planar reconstruction (MPR)

& linear reconstructions of the cochlea, so it can be applied during clinical routine and precede every cochlear implantation (CI) surgery. [4, 5] CT is also used to identify the osseous anatomy and malformations of the external, middle and inner ear. [6].

Magnetic resonance imaging (MRI) is used to study the membranous labyrinth, eighth cranial nerve and coexistent brain abnormalities. [6].

The introduction of electrodes of variable length creates a need to develop a preoperative technique to determine the length of the patient's cochlea, and to choose the correct electrode size for the patient which allow to provide proper cochlear coverage & improve the postoperative outcomes and avoiding any insertional trauma. [7].

For years, the length and morphology of the human cochlea has been studied, Considerable variations of the cochlear duct length (CDL) between individuals have been found. [7] Cochlear duct length estimation may predict the cochlear implant depth of insertion. [8].

The insertion depth of the implanted electrode can be described in terms of linear distance in mm or insertion angles in degrees, several studies have demonstrated that greater angular insertion depths result in better speech perception & performance. [9, 10].

2. Patients and Methods

This study was conducted in Radio-diagnosis Department, Tanta University hospitals between November 2015 to March 2018.

2.1. Inclusion Criteria

Patients over two years of age.

Patients who have bilateral profound or severe hearing loss if there is no enough benefit from external hearing aid.

2.2. Exclusion Criteria

Mild or moderate degrees of sensory neural hearing loss.

Patient with congenital inner ear anomalies.

Non –contrast enhanced computed tomography (CT) of the petrous bone was performed using general electric (GE) medical systems-optima CT 660, 128 slices. Uncooperative pediatric patients (n= 4) were orally sedated.

The images were obtained in 0.625 mm slice thickness, 0.5 s rotation time; 0.725 pitch factor; 140 kV tube voltage; 125 mA tube current; and a 240-mm scan field of view (FOV). In bone algorithm images, Window width and level were adjusted until the small anatomic features could be visualized.

2.3. Image Reconstruction and Post Processing

2.3.1. Double Oblique Coronal Reconstruction

i. It was obtained by aligning the multiplanar reconstruction axes on the axial and sagittal planes parallel to the basal turn and perpendicular to the modiolus.

ii. The cochlear distance (CD) (Distance A –basal turn diameter) was measured from the midpoint of the long diameter of the round window through the mid-modiolar axis to the opposite wall of the basal turn.

iii. Distance A is then used to calculate the cochlear duct length (CDL) using the following equation to obtain full coverage of the cochlea:

$$CDL=4.16xA-3.98. [11]$$

iv. A perpendicular distance (distance B) representing the width of the basal turn was also measured.

2.3.2. Post-Operative Assessment

i. All patients were operative using a round window approach.

ii. A normal placement of the implant was indicated by

demonstrating.

The electrodes to be regularly spaced and the electrode array curving gently within the first turn of the cochlea.

iii. The following electrodes were used with their lengths as follows:

MED-EL Standard= 31 mm, FLEX 28™ =28 mm, Cochlear NucleusCI24RE with Full-Band Straight Electrode=17 mm, HiFocus SlimJ Electrode Description (Advanced bionics) =23 mm and Oticon implant device (The EVO® electrode array) = 24 mm.

2.3.3. Measurement of Angular Insertion Depth

The 3 most apical electrodes were identified and used to create a circle depicting their course. A line drawn from the insertion point to the center of this circle served as the reference (zero degree) line. The angle between the most apical electrode and the reference line was calculated.

This angle (was subtracted from or added to 360 or 720, depending on the relationship between the apical electrode and the number of turns across the reference line.

3. Results

This study was conducted at the university of Tanta between November 2015 to March 2018. Forty patients were recruited with mean age 24.63 ± 17.30 years (range , 4 to 57 years) .Years of profound deafness before the operation ranged between 0.5 to 23 years with a mean 6.40 ± 5.01 (Table 1).

In the majority of cases 72.5% (29 cases) the etiology of hearing loss was unknown, 3 cases (7.5%) suffered from post-febrile illness , cases with positive family history of hearing loss and those who suffered from birth asphyxia were equal ,each was represented by 2 cases (5%).

The other causes including: ototoxic drug intake, meningitis, diabetes and Meniere's disease, each was present in one case (2.5%).

The cochlear distance (diameter A), and the perpendicular distance (diameter B) were measured for 80 ears (40 patients) before the operation and the cochlear duct length were also calculated, the results are summarized in table 2.

Width of the cochlear base (Distance -B): the range, the mean and the standard deviation for the right ear were 5.4 – 6.4, 5.9 ± 0.26 and for the left ear were 5.6 – 6.6, 6.02 ± 0.26 .

For the left ear the mean cochlear duct length for male = 31.41 ± 3.12 while for female = 31.11 ± 1.48 ($p=0.699$ & t -test = 0.389).

No correlation found between the patient age and CDL (P value for the right ear = 0.503 and for the left ear = 0.14).

Also, no significant difference was found between the mean CDL between male and female for the right and the left ears (for the right ear, the mean CDL for male = 31.66 ± 2.18 while for female = 31.63 ± 2.44 ($P=0.974$ & t -test = 0.033).

A non-significant correlation was found between the mean cochlear duct length in the right (31.65 ± 2.29) and the left

(31.25 ± 2.37) ears (independent sample t-test =0.897 p=0.375).

A statistically significant positive correlation was found between the Distance –A and the cochlear width (diameter B) for the right ear (p=0.033) but no statistically significant correlation was found between them for the left ear.

In the current study, 23 (57.5%) patients received the cochlear implant in the right ear while the remaining patients 17 (42.5%) received it in the left ear. The distribution of the studied cases according to the type of the implanted electrode is shown in table 3.

The parameters of the cochlea for the implanted ears (n= 40) were demonstrated as in table 4.

The relation between type of implanted electrode and insertion depth angles as in table 5.

For each electrode array a significant positive correlation was found between the insertion depth angle and the length of the electrode array.

Correlation between insertion depth angle, cochlear size represented by cochlear distance (diameter A) and cochlear duct length for the implanted ears.

NO statistically significant correlation was found between the cochlear size represented by (diameter A) and the insertion depth angles for different type of electrodes (r=-0.020, p=0.901).

Table 1. Distribution of the studied cases according to demographic data (n= 40).

	N	%
Age at implantation		
<10	13	32.5
10 – 20	7	17.5
20 – 30	4	10.0
30 – 40	5	12.5
40 – 50	8	20
≥50	3	7.5
Min. – Max.	4.0 – 57.0	
Mean ± SD.	24.63 ± 17.30	
Median	20.50	
Sex		
Male	19	47.5
Female	21	52.5
Years of profound deafness		
0 - < 5	17	42.5
5 - < 10	17	42.5
10- < 15	3	7.5
15 - < 20	1	2.5
≥20	2	5.0
Min. – Max.	0.50 – 23.0	
Mean ± SD.	6.40 ± 5.01	
Median		

N=Number, %=percentage

Table 2. Description of the studied cases according to different cochlear parameters (n= 80).

	Min. – Max.	Mean ± SD.	Median
Cochlear distance(diameter A)	7.10 – 10.10	8.53 ± 0.56	8.55
Cochlear duct length	25.50 – 38.0	31.45 ± 2.33	31.55
Cochlear width (diameter B)	5.40 – 6.60	5.98 ± 0.26	5.95

Min=minimum, Max=Maximum, SD=standard deviation

Table 3. Distribution of the studied cases according to type of implanted electrode (n= 40).

Type of implanted electrode	No	%
Advanced Bionic	6	15.0
Cochlear Nucleus	9	22.5
Flex 28	7	17.5
Med El standard	17	42.5
Oticon	1	2.5

Table 4. The parameters of the cochlea for the implanted ears (n= 40) were as follow.

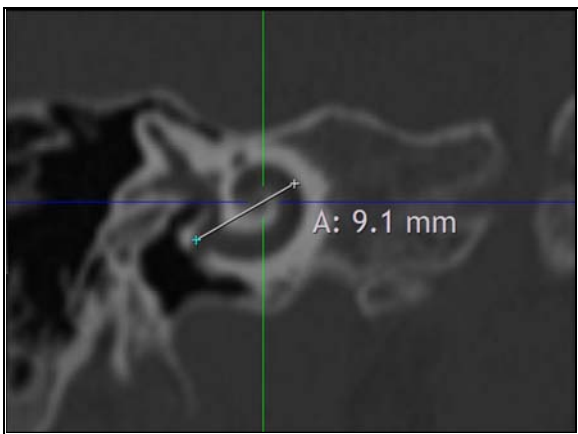
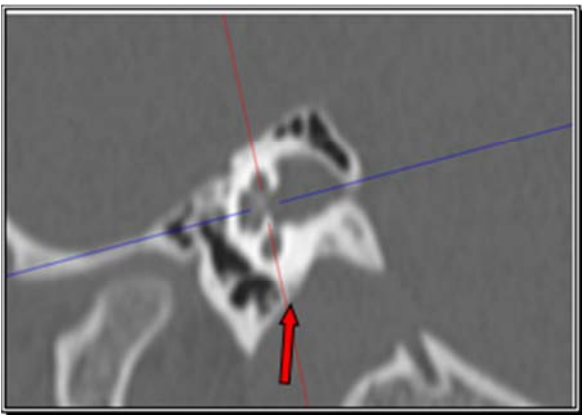
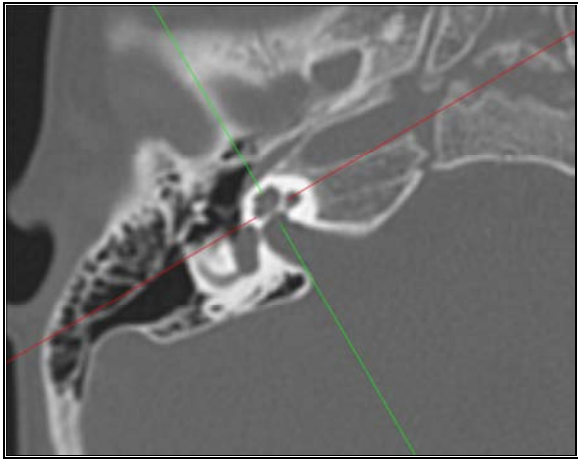
Implantation	Min – Max	Mean ± SD.	Median
Cochlear distance (Diameter A)	7.10 – 9.80	8.44 ± 0.64	8.55
The whole cochlear length	25.50 – 36.70	31.11 ± 2.65	31.55
Cochlear width (diameter B)	5.40 – 6.50	5.93 ± 0.26	5.90

Table 5. Relation between type of implanted electrode and insertion depth angles.

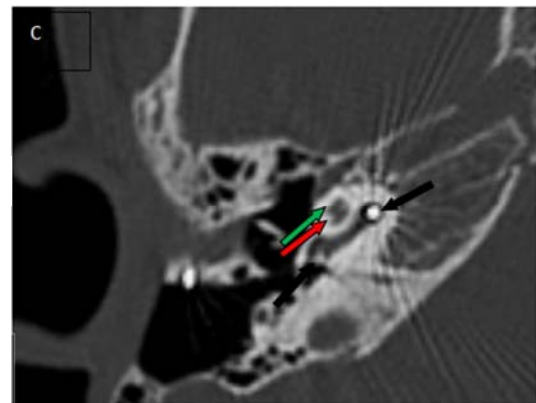
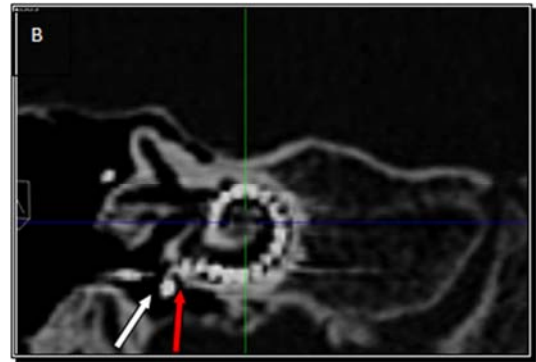
Insertion depth angle	Type of implanted electrode				F	p
	Cochlear nucleus (n= 9)	Advanced bionics (n= 6)	Flex 28 (n= 7)	Med El standard (n= 17)		
Min. – Max.	211.0 – 420.0	405.0 – 500.0	371.0 – 520.0	475.0 – 598.0		
Mean ± SD.	367.56 ± 71.81	450.17 ± 36.77	456.14 ± 61.33	513.06 ± 31.76	360.0	13.634*
Median	395.0	446.50	487.0	511.0		<0.001*

F, p: F and p values for ANOVA test for association between type of implanted electrode and Insertion depth angle.

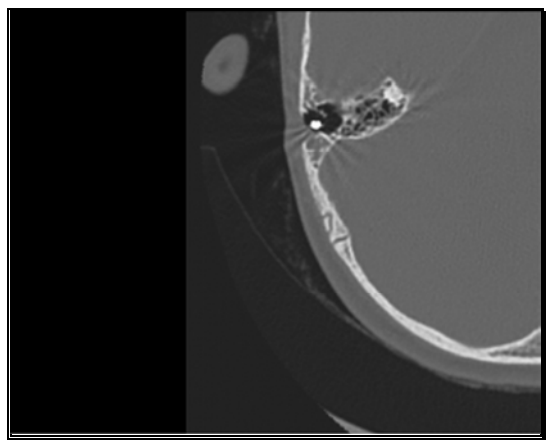
*: Statistically significant at $p \leq 0.05$.



(A): Multiplanar reconstruction images of the right cochlea with the multiplanar reconstruction axes are aligned parallel to the basal turn on the axial (A1) and sagittal (A2) planes to generate a coronal oblique (A3) image of the cochlea ,the Cochlear distance (distance A)= 9.1mm & the whole cochlear duct length=33.8mm.



(B): Coronal oblique reconstruction of the right sided cochlear implant revealed insertion depth angle =360° with single extracochlear electrode contact (basal electrode) is noted (white Arrow), the red arrow denoting the insertion point. (C): Axial view of the right cochlea show the electrode contacts in the basal turn (black arrows) with no contacts are seen in the middle (red arrow) or apical turns (Green Arrow).



(D): Opacification of the right mastoid air cells (right mastoiditis) is noted.

Figure 1. Male patient aged 7 years, the right ear implanted with Oticon cochlear implant.

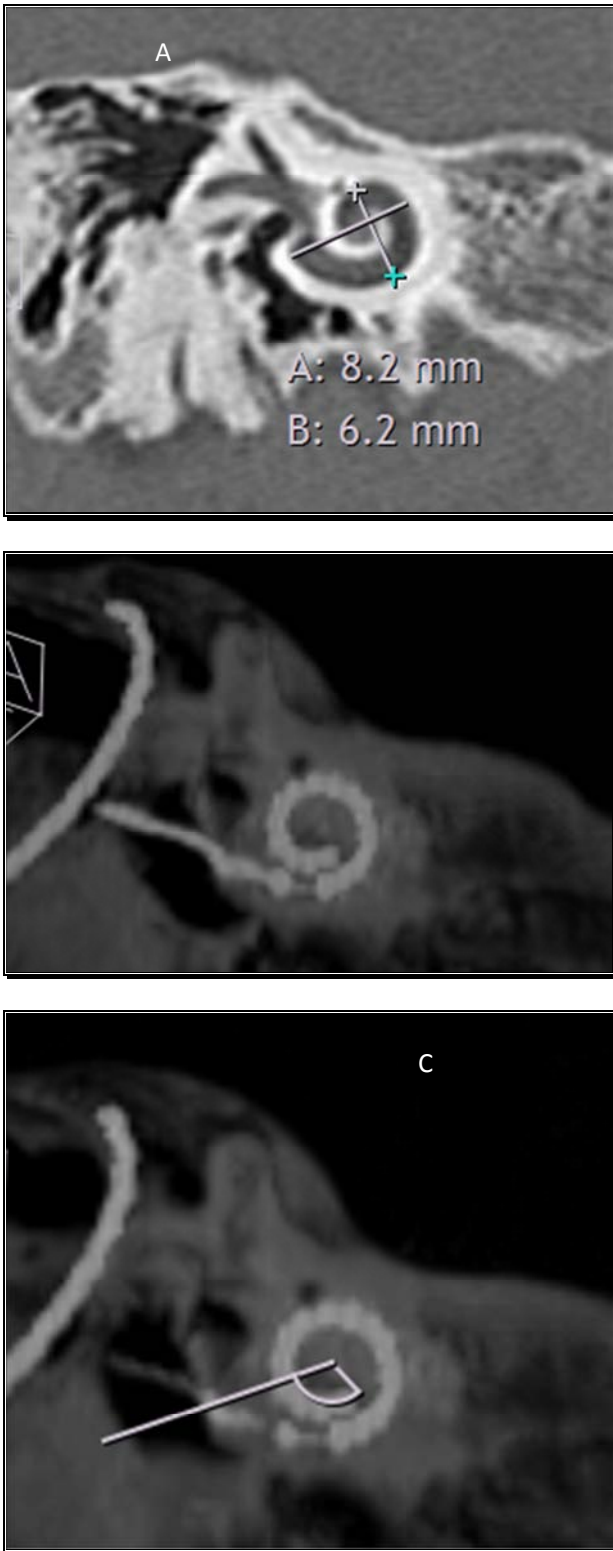


Figure 2. Female patient aged 6 years with the right ear implanted with advanced bionics implant.

(A): Double coronal oblique reformatted steeper projection of the right cochlea showing the cochlear distance (Distance A) = 8.2mm and the perpendicular distance (cochlear width–Distance B) = 6.2 mm. (B & C): post-operative double coronal oblique reconstruction of the right sided cochlear implant (minimum intensity projection -MIP) revealed insertion depth angle = 473° (360+113°) with complete insertion of the cochlear implant.

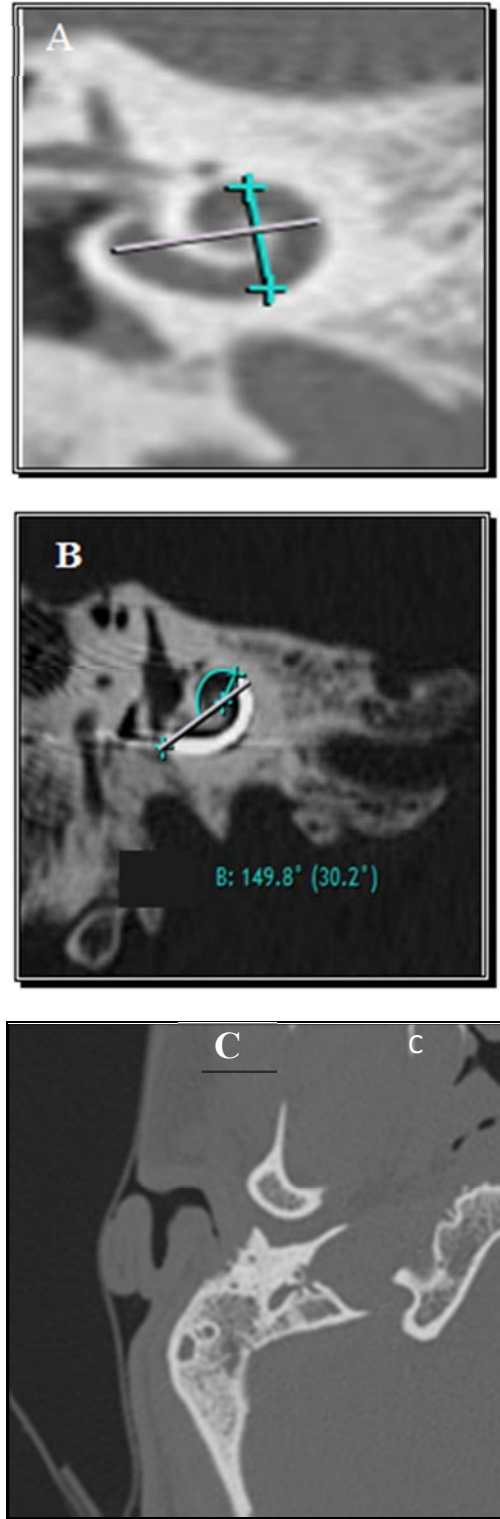


Figure 3. Male patient aged 24 years implanted with cochlear nucleus implant.

(A): Double coronal oblique reformatted steeper projection of the left cochlea showing the cochlear distance (Distance A) = 8.4 mm and the perpendicular distance (cochlear width –Distance B) = 5.8 mm. (B): Post-operative double oblique coronal reconstructed image the electrode contacts makes less than one complete turn, insertion depth angle = 211°. (C): Opacification of the right mastoid air cells in the post-operative images (right mastoiditis) is noted.

4. Discussion

This study evaluated the role of MDCT in preoperative prediction of the best cochlear implant electrode length with detection of the variations in cochlear size that may influence the final maximum insertion depth angle achieved with cochlear implant electrode arrays.

In the current study, the etiology of hearing loss was unknown in the majority of patients, 29 patients out of 40 patients (72.5 %). This is in agree with Chaturvedi et al [12] where most of the patients, 10 out of 30 patients (33.3%), also had unknown etiology while the remaining 20 patients are distributed among the other causes.

The measured cochlear distance (diameter A) ranged from 7.1 to 10.1mm with a mean diameter of 8.5mm (SD=0.56). The studied left ears yielded a smaller mean diameter amounting to 8.48 ± 0.57 compared to the group of the right ears yielding a mean diameter of 8.58 ± 0.55 .

The current study findings are in line with the study conducted by Kuthubutheen et al [13], who studied the effect of the cochlear duct length on electrode insertion in cochlear implantation, the measured basal turn diameter (Diameter A) in this study ranged from 7.3 to 9.8mm with a mean diameter 8.5 ± 0.49 .

Grover et al [14] had reported shorter diameters in a study conducted on the Asian Population with mean of distance A for right ear was 8.10 mm (range 7.7–9.2 mm) and mean for the same in left ear of these patients was 8.14 mm (range 7.7–9.0 mm), giving an overall average of 8.12 mm, this was attributed to racial variations.

A statistically significant positive correlation was found between the Distance –A and the cochlear width (diameter B) for the right ear ($p=0.033$) but no statistically significant correlation was found between them for the left ear.

Meng et al [15] found a statistically significant positive correlation between diameter A & B for both ears which is in partial disagreement with our study. The measured cochlear duct length ranged between 25.5-38 mm with a mean diameter 31.45 ± 2.33 .

Meng et al [15] measured CDL at the lateral wall, after analyzing 310 of their own clinical CT scans, they found a range of 30.7mm to 42.2mm with an average of 35.8mm.

In this study, there was no correlation found between the patient age, sex, side and cochlear duct length.

Würfel et al [16] and Escudé et al [17] also reported that no statistically significant difference in the cochlear duct length compared to the age and side which is in agree with the current study. But they reported that there is a statistically significant difference in the cochlear duct length between males and females.

The measured insertion depth angle ranged between 211° – 598° with a mean insertion depth angle $457.1^\circ \pm 75.42$.

A statistically significant difference was found between the length of the electrode and the insertion depth angles. This observation is consistent with the assumption that a longer electrode penetrates deeper into the cochlea.

In the retrospective study of Franke-Triegeer et al [18] 20

females and 17 males were implanted with a Cochlear CI422 with Slim Half-Band Straight Electrode. The measured insertion depth angle ranged from 306° to 579° (mean $444 \pm SD 63$). And revealed a positive correlation between the linear insertion depth and the measured angles, this is in agree with the current study.

In this study, no statistically significant correlation was found between the basal turn diameter A and insertion depth angle ($r=-0.020$, $p=0.901$).

Franke-Triegeer et al [19] tested the hypothesis that the insertion depth angle as a function of the diameter of the basal turn of the cochlea. A statistically significant negative correlation between the insertion depth angle and the diameter of the basal turn of the cochlea was found for the 20-mm group ($R2 = 0.62$; $p = 0.006$) and the 31-mm group ($R2 = 0.70$; $p = 0.018$). The FLEX24 ($R2 = 0.40$; $p = 0.095$) and the FLEX28 ($R2 = 0.26$; $p = 0.195$) group failed to be statistically significant.

The limitations of this study was the small sample size, the measurement techniques are operator dependent and should be correlated with more reliable methods for cochlear duct length estimation as histopathologic and/or micro CT.

5. Conclusion (Edited –Bullets Were Removed)

Assessment of the cochlear parameters is used detect the variability in the cochlear morphology and the cochlear duct length among the individuals candidates for cochlear implantation. These parameters should be included in the radiological report prior to the operation, which helps to choose the most appropriate electrode for the patient. This selection of electrode is crucial as the electrode must provide proper cochlear coverage to improve the postoperative outcomes while avoiding any insertional trauma which may result from a deep insertion.

References

- [1] Verbist BM. Imaging of sensorineural hearing loss: A pattern-based approach to diseases of the inner ear and cerebellopontine angle. *Insights Imaging*. 2012;3(2):139-153.
- [2] Miyasaka M, Nosaka S, Morimoto N, et al. CT and MR imaging for pediatric cochlear implantation: Emphasis on the relationship between the cochlear nerve canal and the cochlear nerve. *Pediatr Radiol*. 2010;40(9):1509-1516.
- [3] Kutz JWJ, Lee KH, Isaacson B, et al. Cochlear implantation in children with cochlear nerve absence or deficiency. *Otol Neurotol Off Publ Am Otol Soc Am Neurotol Soc [and] Eur Acad Otol Neurotol*. 2011;32(6):956-961.
- [4] Kissner U, Ertl-Wagner B, Hempel JM, et al. High-resolution computed tomography-based length assessments of the cochlea--an accuracy evaluation. *Acta Otolaryngol*. 2014;134(10):1011-1015.

- [5] Lee CH, Goo JM, Ye HJ, et al. Radiation dose modulation techniques in the multidetector CT era: from basics to practice. *Radiographics*. 2008;28(5):1451-1459.
- [6] Joshi VM, Navlekar SK, Kishore Gr et al. CT and MR Imaging of the Inner Ear and Brain in Children with Congenital Sensorineural Hearing Loss. *RadioGraphics*: 2012;32(3):683-698.
- [7] Koch RW, Ladak HM, Elfarnawany M, et al. Measuring Cochlear Duct Length - A historical analysis of methods and results. *J Otolaryngol - Head Neck Surg*. 2017;46(1):1-11.
- [8] Nayak G, Panda NK, Banumathy N, et al. Deeper insertion of electrode array result in better rehabilitation outcomes - Do we have evidence? *Int J Pediatr Otorhinolaryngol*. 2016;82:47-53.
- [9] Lee J, Nadol JB and Eddington DK. Depth of electrode insertion and postoperative performance in humans with cochlear implants: A histopathologic study. *Audiol Neurotol*. 2010;15(5):323-331.
- [10] Rivas A, Cakir A, Hunter JB, et al. Automatic Cochlear Duct Length Estimation for Selection of Cochlear Implant Electrode Arrays. *Otol Neurotol*. 2017;38(3):339-346.
- [11] Adunka O, Unkelbach MH, Mack MG, et al. Predicting basal cochlear length for electric-acoustic stimulation. *Arch Otolaryngol Head Neck Surg*. 2005;131(6):488-492.
- [12] Chaturvedi A, Mohan C, Mahajan S, et al. Imaging of cochlear implants. *Indian J Radiol Imaging*. 2006;16(3):385-392.
- [13] Kuthubutheen J, Grewal A, Symons S, et al. The effect of cochlear duct length on hearing outcomes in hearing preservation cochlear implantation Methods. *Sunnybrook health sciences center*. 2014;35(1):3.
- [14] Grover, M., Sharma, S., Singh, S.N. et al. Measuring cochlear duct length in Asian population: worth giving a thought. *Eur Arch Otorhinolaryngol*. 2018 ; 275(3):725-728
- [15] Meng J, Li S, Zhang F, et al. Cochlear Size and Shape Variability and Implications in Cochlear Implantation Surgery. *Otol Neurotol Off Publ Am Otol Soc Am Neurotol Soc [and] Eur Acad Otol Neurotol*. 2016;37(9):1307-1313.
- [16] Würfel W, Lanfermann H, Lenarz T, et al. Cochlear length determination using Cone Beam Computed Tomography in a clinical setting. *Hear Res*. 2014;316 :65-72.
- [17] Escudé B, James C, Deguine O, et al. The size of the cochlea and predictions of insertion depth angles for cochlear implant electrodes. *Audiol Neurotol*. 2006;11(SUPPL. 1):27-33.
- [18] Franke-Triege A and Mürbe D. Estimation of insertion depth angle based on cochlea diameter and linear insertion depth: a prediction tool for the CI422. *Eur Arch Oto-Rhino-Laryngology*. 2015;272(11):3193-3199.
- [19] Franke-Triege A, Jolly C, Darbinjan A, et al. Insertion depth angles of cochlear implant arrays with varying length: A temporal bone study. *Otol Neurotol*. 2014;35(1):58-63.