

The Role of Ultrasonography and Computerized Tomography in the Diagnosis of Pediatric Cystic Neck Swellings

Mohamed Mohamed Abomosllam¹, Rehab Mohamed Habib², Hala Hafez Mohamed²

¹Radiology Department, Portsaid General Hospital, Port Said, Egypt

²Radiology Department, Faculty of Medicine, Menoufia University, Shbine Elkoom, Egypt

Email address:

hefezhala@yahoo.com (H. H. Mohamed), rehab_habib77@yahoo.com (R. M. Habib),

Dr_mohammed.abomosllam@yahoo.com (M. M. Abomosllam)

To cite this article:

Mohamed Mohamed Abomosllam, Rehab Mohamed Habib, Hala Hafez Mohamed. The Role of Ultrasonography and Computerized Tomography in the Diagnosis of Pediatric Cystic Neck Swellings. *International Journal of Medical Imaging*.

Vol. 3, No. 2, 2015, pp. 21-27. doi: 10.11648/j.ijmi.20150302.13

Abstract: Objectives: This study aimed to evaluate the role of US and CT in the diagnosis of pediatric cystic neck swellings. Background: Pediatric cystic neck swellings represent a major group of lesions that have long been a challenge to both clinicians and radiologists. US is an inexpensive, bedside and noninvasive technique while CT is the imaging modality of choice in characterization and staging of deep neck spaces cystic swellings. Methods: This prospective study included 72 children suffering from neck swellings. Forty two patients were found to have solid neck swellings while 30 patients represent this study population. US examination of the neck was performed for all patients in order to determine the nature of the swelling (cystic or solid), identify its origin, morphologic features & size in contrast to CT neck examination. Results: Male to female was 17 to 13, their ages ranged from 2 days and 18 years with a mean age of 8.5 years. Salivary gland abscess was the most common cause of neck swellings (20%) & thyroglossal cyst (16.6%) & cystic hygroma, retropharyngeal abscess, 2nd branchial cyst (10%) for each & parapharyngeal abscess, non tuberculus lymphadenitis with cystic degeneration, colloid goiter (6.6%) for each. Thirteen patients out of thirty had cystic neck swellings of congenital origin including cystic hygroma, branchial cyst, dermoid cyst, ranula & thyroglossal cyst. Conclusion: US is the prime investigation for patients suspected of having cystic neck swellings and was the first step in the diagnosis while CT scan was a sensitive tool for imaging and we recommend it as a confirmative imaging method.

Keywords: Cyst, Swelling, Echogenicity, US

1. Introduction

Lesions involving the pediatric neck are common and may involve any of the soft tissue, vascular, or osseous structures contained within this space ⁽¹⁾. The optimal evaluation and management of pediatric neck masses relies on a clear understanding of neck anatomy and the pathogenesis of specific disorders ⁽²⁾. Cystic or cyst-like neck masses form a unique category within head and neck radiology with unique differential diagnoses, as it arises from a variety of underlying conditions, such as congenital, inflammatory, neoplastic, or infectious conditions ⁽³⁾.

Several imaging techniques, including radiography, gray-scale and Doppler US, conventional and three-dimensional CT have been proposed for the evaluation of such lesions,

and each has its own advantages. US provides a rapid, relatively inexpensive, bedside, noninvasive technique that does not require sedation & does not involve radiation hazards; all of which are significant issues in the evaluation of various causes of neck swellings in the pediatric age group ⁽⁴⁾. With its non invasive ability US helps to define the size and extent of localized superficial masses and to confirm their cystic or solid nature ⁽⁵⁾. Color Doppler ultrasound can assess mass vascularity as well as evaluate patency of blood vessels, flow direction and analysis of flow velocity waveform which provides great help in establishing an accurate diagnosis ⁽⁶⁾. CT has rapidly become the imaging modality of choice in evaluation of swellings of deep neck spaces that cannot be demonstrated by US. It provides excellent spatial resolution, superior tissue contrast that

allows precise visualization of fine bone structures, calcifications, and aid in the morphologic characterization and staging of the neck swellings (7).

State-of-the-art CT of the head and neck requires the use of MDCT. Its main advantages are faster scanning time and increased volume coverage result in an increased number of slices obtained within a certain amount of time (8).

The aim of this work is to highlight the role of ultrasonography and computerized tomography in the diagnosis of pediatric cystic neck swellings.

2. Patients and Methods

2.1. Patients

This prospective study was carried out on 72 children suffering from neck swellings. Their ages ranged between 2 days and 18 years. A meticulous US examination of the neck was performed for all patients in order to determine the nature of the swelling (cystic or solid), identify its origin, morphologic features & size. Forty two patients were found to have solid neck swellings & thus were excluded from the study. The remaining 30 patients represent this study population. They were 17 males & 13 females. All patients underwent full history taking & clinical examination & laboratory work up and biopsy & imaging work up in the form of US and CT while MRI, panoramic x-ray, chest X-ray and Sialography were done for some cases.

2.2. Ultrasonography

Gray-scale US coupled with color Doppler flow imaging was performed to all patients using a high frequency (7-15 MHz) linear-array two dimensional transducers. Color & spectral Doppler analysis were performed to locate any abnormal vessels or vascularized tissue within the cysts. Maximum peak flow velocity, arterial resistive and pulsatile indices were automatically calculated while color gain was adjusted manually to maximize visualization of small blood vessels and detect low-velocity arterial and venous flow. The infants & neonates were examined while lying on their mother's laps; while children & adolescent were examined lying supine with hyperextended neck. Scanning planes were mainly transverse and longitudinal. The morphological features including swelling location and its relation to the surrounding structures & wall thickness & echogenicity & vascularity of swelling were evaluated.

2.3. Computerized Tomography

CECT scan of the neck was done after explanation of the

procedure and it's contraindications to the patients and/or their parents. All patients were examined by a 16 detectors CT scanner. Children younger than 5 years were sedated using oral chloral hydrate 50-100 ml/Kg. Iodinated contrast agent was given IV in a dose of 1ml/Kg. A single bolus was injected at a rate of 1cc/s. On a lateral scout view, the area of interest was indicated. Images were acquired from the top of the sphenoid sinus to lower border of sternoclavicular joints. The head is aligned in cephalocaudal axis. The images were obtained with the patient supine with slightly extended neck. Axial cut sections were taken with a thickness of 4-5mm.

2.4. Statistical Analysis

Quantitative & qualitative data was presented as number and percentage. Comparison between the different causes of pediatric cystic neck swellings was done.

3. Results

Thirty pediatric patients presenting with cystic neck swellings represent the study group of this thesis. Four patients showed a midline neck swelling while twenty six had a lateral neck swelling. Salivary gland abscess was the most common cause of neck swellings (6 patients) followed by thyroglossal cyst (5 patients) while cystic hygroma, retropharyngeal abscess & branchial cyst were seen in 3 patients each. Thirteen patients out of thirty had cystic neck swellings of congenital origin including cystic hygroma (3 patients), branchial cyst (3 patients), dermoid cyst (1 patient), ranula (1 patient) (Table 1). All cystic neck swellings were clearly diagnosed by US. A well-defined, anechoic, a vascular lesion with posterior acoustic enhancement was the common feature of the examined neck cysts. The diagnosis of the cystic neck swellings according to the tissues of origin was seen in table 2. 24 cysts were anechoic while 6 showed heterogenous echogenicity. 25 cysts were unilocular while 5 showed multiloculation. 23 cysts showed regular walls & 7 had irregular walls. The data in table 3 also showed that 24 cysts had fluid density by CT scan while 6 showed mixed density. 23 cysts showed regular outlines & 7 cysts had irregular walls. There was no post contrast enhancement in 15 cysts. Peripheral enhancement was seen in 12 cysts (Table 3). CT confirmed the US diagnosis in 24 out of 30 patients with an accuracy of 80%. Four cysts showed signs of complication in the form of increased wall thickness, turbid echogenic debris, and internal septations. One patient showed a clinically detectable cutaneous opening in relation to the thyroglossal cyst.

Table No. 1. Shows the final pathological diagnosis of all patients according to their age group.

Lesion	Age				Total
	Neonate	Infant	Children	Adolescent	
Salivary gland abscess	-	2	2	2	6
Ranula	-	-	-	1	1
Para pharyngeal abscess	-	1	1	-	2
Retro pharyngeal abscess	1	-	1	1	3

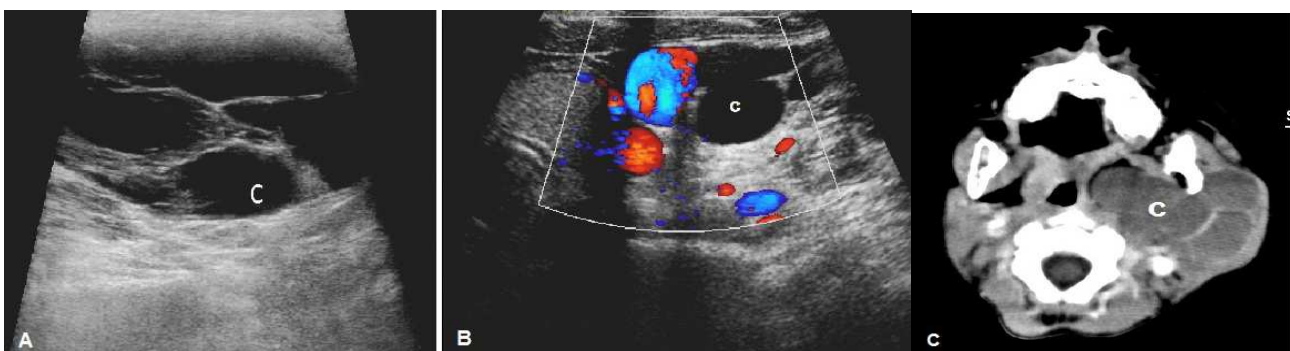Lesion	Age				Total
	Neonate	Infant	Children	Adolescent	
Branchial cyst	-	-	2	1	3
Dermoid cyst	-	-	-	1	1
Cystic hygroma	1	1	1	-	3
Tuberculus lymphadenitis with central caseation	-	-	1	-	1
Non tuberculus lymphadenitis with cystic degeneration	-	-	1	1	2
Colloid cyst	1	-	-	1	2
Thyroglossal cyst	1	-	3	1	5
Complex thyroid cyst	-	-	-	1	1
Total	4	4	12	10	30

Table No. 2. Shows the diagnosis of the cystic neck swellings according to the tissues of origin.

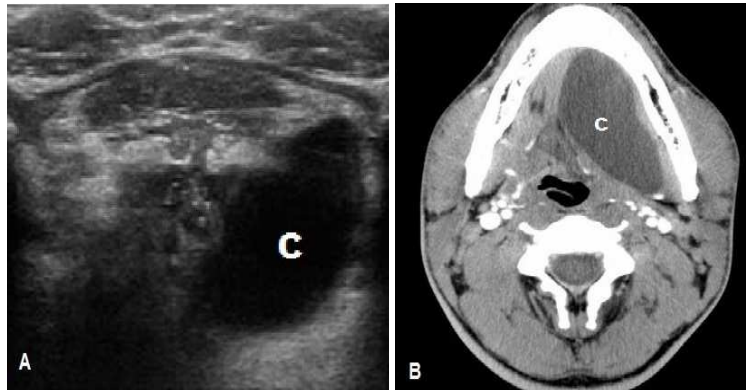
Origin of the lesion	No.	%
Salivary gland	7	23.3
Thyroid gland	8	26.6
Lymph nodes	6	20
Branchial apparatus	3	10
Soft tissue	5	16.6
Skin	1	3.3

Table No. 3 Shows the radiological features of cystic neck swellings.

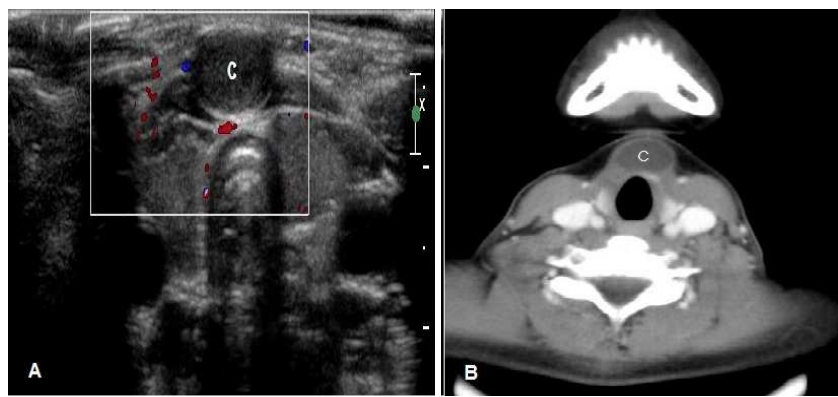
Radiological Features	Number	%	
<i>US features</i>			
Echogenicity	Anechoic	24	80
	Heterogeneous	6	20
Content	Clear	24	80
	Unclear	6	20
Loculation	Uniloculated	25	83.3
	Multiloculated	5	16.6
Wall	Regular	23	76.6
	Irregular	7	23.3
<i>CT features</i>			
Density	Fluid	24	80
	Mixed	6	20
Outline	Regular	23	76.6
	Irregular	7	23.3
Pattern of enhancement	No enhancement	15	50
	Peripheral enhancement	12	40
	Heterogeneous enhancement	3	10



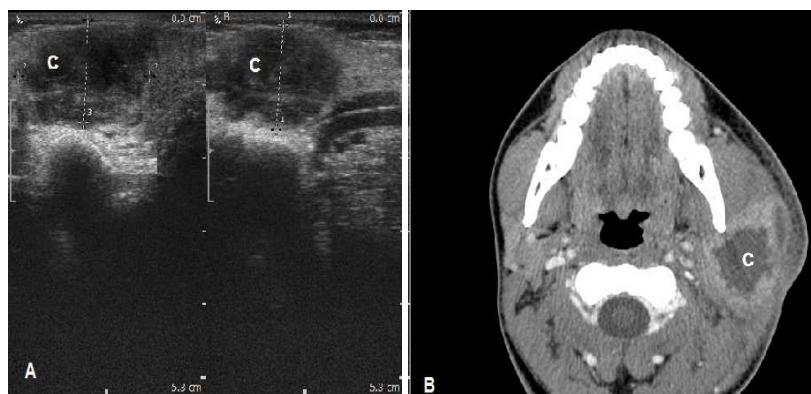
Case No. (1) Fig.1 (A) B-mode US transverse scan at the level of the left posterior triangle of the neck revealed a well-defined oval shaped cyst (C) in the anterolateral compartment of the left side of the neck. The cyst measured 4x5 cm and showed thick internal septations. (B) Color Doppler US transverse scan revealed no vascular signal inside the cyst (C). The cyst is not compressing internal jugular vein or common carotid artery. (C) Axial CECT of the neck at the level of the hyoid bone revealed a well-defined multi-loculated cyst (23 HU) (c) in the left posterior triangle of the neck. The cyst measured 4x8x5 cm and showed no enhancement after contrast injection. It was seen extending to the parapharyngeal space displacing the parapharyngeal fat and nasopharynx to the right side. The final diagnosis after US, CT, and histopathological study was cystic hygroma in the anterolateral compartment of the left side of the neck.



Case No. (2) Fig.2 (A) B-mode US transverse scan at the level of the sublingual gland revealed a well-defined, unilocular cyst (c) in the left sublingual space beneath the left mylohyoid muscle. The cyst measured 2.7x0.9 cm and showed thin-wall & clear content. (B) Axial CECT of the neck at the level of CV3 showed a well defined cyst (12 HU) (c) arising from the left sublingual gland. The cyst measured 2.7x0.9 cm and showed no enhancement after contrast injection. The final diagnosis after US, CT, and surgical excision was a simple ranula of the left sublingual gland.



Case No. (3) Fig.3 (A) B-mode & Color Doppler US transverse scan at the level of thyroid cartilage revealed a well-defined round unilocular cyst (c) infrahyoid in position. The cyst measured 0.6x0.8x1 cm and showed thin-wall. It moved up and down with protrusion of the tongue. Color Doppler US revealed no vascular signal inside the cyst. (B) Axial CECT of the neck at the level of the thyroid cartilage revealed a well defined cyst (15 HU) (c) in the anterior compartment of the neck. The cyst measured 0.6x0.8x1cm and showed no enhancement after contrast injection. The final diagnosis after US, and CT was thyroglossal cyst.



Case No. (4) Fig.4 (A) B-mode US transverse & longitudinal scans at the level of the left parotid gland revealed a well defined cyst (c) in the left parotid gland. The cyst measured 2x1.4x1.4 cm and showed echogenic debris. (B) Axial CECT of the neck at the level of the parotid gland revealed a thick irregular wall cyst (35 HU) (c) in the left parotid gland. The cyst measured 2x1.4x1.5 cm and showed wall enhancement after contrast injection. The final diagnosis after US, and CT was left parotid gland abscess.

4. Discussion

Head and neck radiology has moved forward from simple conventional radiographic examinations to modern sophisticated studies. One of the most frequently encountered difficult diagnostic challenges in the pediatric population is

neck swellings. They include diverse conditions of congenital, inflammatory, neoplastic as well as vascular origins. US plays a vital part in the diagnosis of pediatric disorders; and its role today is more important than ever, while CT has become an indispensable tool in the characterization and staging of the conditions involving the head and neck.

Five patients in our study (1-12 years old) were diagnosed as thyroglossal duct cysts (TDCs). 70% of the TDCs were at the infrahyoid level, midline in location with a size ranged from 5-15 mm. Posterior enhancement was present in 77.8% of our cases. Malik et al ⁽⁹⁾ stated that 65% of TDCs are infrahyoid, 20% suprahyoid and 15% occur at the level of the hyoid bone and are usually detected by the age of 20 years with a size ranged from 15 to 30 mm in diameter. Basha and Yousem ⁽¹⁰⁾ agreed that TDCs are the most common midline neck swellings encountered in children, accounting for about 70% of all congenital neck swellings and this agreed with our study.

Three patients in our study were diagnosed as 2nd branchial cleft cysts. The cysts were anterior and medial to sternocleidomastoid muscle and in the left side with a size ranged from 40-75 mm and age ranged from 2-12 years and no sex predilection detected. These cysts appeared as lobulated thin walled cysts; 100% of the cysts showed posterior enhancement and 2 cysts were unilocular. Tracy and Muratore ⁽⁸⁾ considered branchial cleft anomalies as the second most common congenital head and neck anomalies found in children. Meuwly et al ⁽⁵⁾ study stated that over 90% of branchial cleft anomalies arise from the second branchial apparatus at the anteromedial border of the sternocleidomastoid muscle and this agreed with our study. 70% of the cysts showed posterior enhancement; 82% were unilocular and no sex predilection was reported.

In our study CT played a vital role in visualizing the branchial cysts full extent and their association with the adjacent structures. They appeared as homogeneously low attenuation mass with thin well defined walls; while infected cyst was of high attenuation with a thick irregular enhancing wall. Dumitrescu et al ⁽¹¹⁾ considered CT unable to distinguish branchial cyst from cystic hygroma and this agreed with our study.

Cystic hygroma is the most common form of lymphangioma. Three patients were diagnosed in our study; they arised as painless, soft slowly growing swellings at the lateral side of the neck anterior to the sternomastoid muscle with a size ranged from 18-90 mm. One patient diagnosed soon after birth; while the 2nd patient by the age of 2 years and 1st patient was 14 years old. By US they were typically cystic; 2 cysts showed thin septations and one cyst was devoid of internal septations in which US diagnosis was not clear. Contrast Enhanced Computerized Tomography (CECT) added that the cyst was multiseptated and insinuating itself between the adjacent structures; CECT also demonstrated its anatomical extent before surgery. Boyaci et al ⁽¹²⁾ study agreed with our study as most of their patients were diagnosed under the age of two years, they considered US as a first step in the diagnosis; also considered CT superior than US but not sufficient alone. Kumar et al ⁽¹³⁾ stated that cystic hygroma occupies lower third of the neck, and as it enlarges it passes toward the ear; often the posterior triangle of the neck is mainly involved, also they considered US is useful for characterizing superficial lesions but is poor when there is extension into deep structures of the neck or thoracic cavity

and that agreed with our study. Macdonald et al ⁽¹⁴⁾ stated that cystic hygromas showed lobulations, septations and heterogeneity in all imaging modalities and usually contain fluid levels which disagreed with our study.

Six patients in our study were diagnosed as salivary gland abscesses; 4 males and 2 females in different age groups (2 infants, 2 children, 2 adolescents). 67% of the cysts were at the right side with a size ranged from 10-30 mm and age ranged from 1.5-13 years. They were presented by neck swelling and constitutional symptoms. By US parotid abscess was anechoic with posterior acoustic enhancement and unclear borders, CECT was done to detect the extent and to assess deep parts of the abscess. According to Harnsberger et al ⁽¹⁵⁾; the best diagnostic clue for the submandibular abscess is CECT. In Rizzo and Da mosto ⁽¹⁶⁾ study in which 90% of patients were adolescents; cystic swelling was monolateral and at the level of the inferior border of the mandible. CECT confirmed the diagnosis and this agreed with our study.

One patient in our study 13 years old was diagnosed as simple ranula. The swelling was in the left side of the floor of the mouth extending medially to the midline. US showed that the cyst was unilocular and anechoic; while CECT showed a fluid attenuation mass extending to the sublingual space. Kim et al ⁽¹⁷⁾ stated that ranula with a thick irregular wall and fine internal echo on US and mixed densities and enhancing wall on CT is an infected one.

In our study, one patient was diagnosed as dermoid cyst at the midline of the lower neck measured 19x11mm. It was seen by US as a well defined anechoic cyst with posterior acoustic enhancement; while CT was optimal for determining its the location, the cyst was of mixed fluid and fat densities. The diagnosis was approved by MRI and biopsy. Kovačević et al ⁽¹⁸⁾ stated that a unilocular midline cystic neck swelling at the suprasternal notch in a child suggests a dermoid cyst, while epidermoid cysts are most often located in the submental region. Basha and Yousem ⁽¹⁰⁾ stated that dermoid cysts occur during infancy at the sublingual space, and it is the 2nd most common midline cystic neck swellings.

Two patients in our study were diagnosed as colloid cysts in the thyroid gland with ages 10 days and 16 years. The size ranged from 5-30 mm. One of the patients showed single cyst in the left lobe and the other showed single cyst in each lobe of the gland. On US the cysts were well defined anechoic with comet tail artifacts. Final diagnosis was achieved by aspiration cytology.

One patient with tuberculosis lymphadenitis and central caseation was reported in our study; she was a female patient 12 years old. The caseated nodes were the lower deep cervical and supraclavicular groups bilaterally. US features include; nodal matting with loculated central cystic areas that were surrounded by a thick capsule. On CT, the cysts were multichambered (conglomerate nodes) with central lucency and thick rim of enhancement. Histopathological examination and TB mycobacterial culture were the gold standard for confirming the diagnosis as they revealed the acid fast bacilli. In Jha et al ⁽¹⁹⁾ study which included 60 patients with age ranged from 9 month to 62 years; the

commonest age group affected was 11-20 years with male to female ratio 1:1.3. In Abakay *et al* ⁽²⁰⁾ study which included patients in the 2nd and 3rd decades; the affected lymph nodes were at the level of the hyoid bone in the right side of the neck, they were large in size; US demonstrated conglomerated coalesced nodes with central necrosis. In Puiu *et al* ⁽²¹⁾ study the most frequently affected lymph node groups were anterior cervical followed by the submandibular groups.

Two patients in our study were diagnosed by CECT as parapharyngeal abscesses; they were located at the left side of the neck lateral to the oropharynx and hypopharynx with a size ranged from 8-25 mm. Their ages were 4 and 9 years. In our study US failed to reach the diagnosis; it revealed only upper deep cervical lymphadenopathy; while CT was able to reach the diagnosis accurately. In Harkani *et al* ⁽²²⁾ study; the age range of their patients was between 18 months and 72 years with male predominance and CT contributed greatly to the diagnosis, but it has limitations in differentiating abscess from cellulitis of the retropharyngeal space. In Haben *et al* ⁽²³⁾ study the parapharyngeal abscesses were in the right and left sides of the neck. CT accurately assesses their extent. Dođru *et al* ⁽²⁴⁾ found that US was not specific in the diagnosis; it showed only oedema of the soft tissue of the neck and this agreed with our study.

Four patients include tuberculus lymphadenitis with central caseation, non tuberculus lymphadenitis with cystic degeneration, and complex thyroid cysts underwent histopathological examination after radiological evaluation that ascertains the radiological diagnosis in three patients and had uncorrelated diagnosis in one patient.

Out of the 30 patients; 2 patients underwent MRI examination; the 1st patient underwent MRI to achieve the final diagnosis which was dermoid cyst; while the 2nd patient underwent MRA as an adjuvant preoperative method to assess the vascular pattern of cystic hygroma. Three patients underwent X-ray chest postero-anterior view; two of them revealed normal study and the third revealed left side tracheal deviation. One patient underwent digital sialography that revealed stone in the Stenson's duct. Panoramic x-ray was done for one patient and revealed carious root.

CBC was done for 16 patients and thyroid profile for 10 patients. CRP was done for 11 patients. One patient underwent echocardiography to exclude arrhythmia as a thyrotoxic sign.

US had a restricted role in the diagnosis of 4 patients, 1st patient because of his extremely short neck, 2nd patient had diffuse retrosternal extension of thyroid enlargement, 3rd patient showed a large subcutaneous emphysema, and the last one had congenital cervical deformities in the form of kyphoscoliosis. Other limitations of US include the small field of view, restricted depth of penetration especially with high-frequency transducers, difficulty in depicting flat superficial swellings, lack of specificity in the diagnosis of the cystic swelling owing to the viscous nature of the cyst contents. Shalaby *et al* ⁽²⁵⁾ stated that the linear transducers or even convex curved transducers do not conform to the neck

anatomy and this may contribute to limiting views. These technical issues may be resolved by the development of a concave curve high-frequency transducer for adequate maintenance of contact between the probe and skin surface.

US complemented the clinical assessment and thus were useful in patient diagnosis, staging, or management ⁽²⁵⁾. US coupled with color Doppler flow imaging is an important imaging tool as it has the advantages of providing a rapid, relatively inexpensive, cost competitive noninvasive modality. It does not require sedation or intravenous access, providing immediate information and maximizing the patient safety, all of which are significant issues in evaluation of various causes of cystic neck swellings in pediatric age group. Doppler US permits assessment of vascular components of the cysts.

5. Conclusion

Although US of the neck is certainly, not a new technology nor it is a new innovation yet it remains an excellent tool for evaluating the pediatric cystic neck swellings and providing guidance for further intervention. US coupled with color Doppler flow imaging and spectral analysis provide a valuable tool in differentiating vascular anomalies as well as benign from malignant cystic neck swellings. CT was superior to US in the diagnosis of many lesions specially those that were too large to be completely imaged within the ultrasound field. It has a great role in the characterization and staging of conditions involving the neck.

References

- [1] Fefferman NR, Milla SS. Ultrasound imaging of the neck in children. *Ultrasound clinics* 2009; 4:553-569.
- [2] Kadom N, Lee EY. Neck masses in children: current imaging guidelines and imaging findings. Elsevier 2012; 1:7-20.
- [3] Gritzmann N. Sonography of the neck: current potentials and limitations. *Ultraschall med* 2005; 2:185-196.
- [4] Chen A, Otto KJ. Differential diagnosis of neck masses. In Cummings otolaryngology: head & neck surgery by Flint PW, Haughey BH, *et al.* 5th ed. Elsevier. Vol.2, Ch.116:380-462, 2010.
- [5] Meuwly JY, Lepori D, Theumann N, *et al.* Multimodality imaging evaluation of the pediatric neck: technique and spectrum of findings. *RadioGraphics* 2005; 5:931-948.
- [6] Turkington JRA, Paterson A, Sweeney LE, Thornbury GD. Neck masses in children. *The British journal of radiology* 2005; 2:75-85.
- [7] Beyme FB. Sonography of head and neck. *Schweiz Rundsch med* 2004; 7:701-706.
- [8] Tracy TF, Muratore CS. Management of common head and neck masses. *Seminars in pediatric surgery*. Elsevier 2007; 1:3-13.
- [9] Malik A, Rodriguez J, Odita J, Hardjasudarma M. Pediatric neck masses: a pictorial review for practicing radiologist: current problems in diagnostic radiology. *Radiol Pub Med* 2002; 31:146-157.

- [10] Basha M M, Yousem D M, Baltimore. Congenital cystic lesions of the neck. *Journals of applied radiology* 2013; 1:1-11.
- [11] Dumitrescu D, Mitroi M, Simionescu C, Popescu C, Mogoanta C, Cioroianu L, Surlin C, Capitanescu A, Georgescu M. Management of second branchial cleft anomalies. *Romanian journal of morphology and embryology* 2008; 1:69-74.
- [12] Boyaci FN, Karakas E, Yildizhan M, Demir S, Saglam MA, Cullu N, et al .Cervicomedial giant cystic hygroma. *Journal of clinical medicine research* 2013; 1:61-63.
- [13] N Kumar, M Kohli, S Pandey, Tulsi SPS. Cystic hygroma. *Natl J Maxillofac Surg.* 2010; (1):81-85.
- [14] Macdonald AJ, Salzman KL, Harensberger HR. Giant ranula of the neck: differentiation from cystic hygroma. *AJNR* 2003; (4):757-761.
- [15] Harnsberger HR. Diagnostic imaging of head & neck: suprahyoid & infrahyoid neck. *Amirsys-Canada* 2004; 3:7-20.
- [16] Boscolo-Rizzo P, Da Mosto MC. Submandibular space infection: a potentially lethal infection. *International journal of infectious diseases.* Elsevier 2009; 13:327-333.
- [17] Kim SH, Huh KH, Park JW, Yi WJ, An CH. Giant plunging ranula. *Imging science in dentistry* 2013; 43:55-58.
- [18] Petrović S, Petrović D, Pešić Z, Kovačević P. Sonography of congenital neck masses in the children. *Medicine and biology* 2005; 3:164-169.
- [19] Jha BC, Dass A, Nagarkar NM, Gupta R, Singhal S. Cervical tuberculous lymphadenopathy: changing clinical pattern and concepts in management. *Postgrad Med J* 2001; 7:185-187.
- [20] Abakay O, Sen HS, Sezgi C, Abakay A, Sabaz OF, Isık R. A chronic ulcerative wound in the neck and disseminated tuberculosis. *Grandrounds, e-med* 2013; 13:52-56.
- [21] Puiu I, Stancu P, Bulucea D, Niculescu C, Nicolescu EV, Stoian F. Diagnosis of tuberculosis lymphadenitis in children. *American Academy of Pediatrics, Pediatrics* 2008; 121-130.
- [22] Harkani A, Hassani R, Ziad T, Aderdour L, Nouri H, Rochdi Y, et al. Retropharyngeal abscess in adults. *The scientific world journal* 2011; 11:1-7.
- [23] Haben CM, Campisi P, Sweet R. Sequential parapharyngeal abscesses: case report. *International journal of pediatric otorhinolaryngology.* Elsevier 2001; 5:255-258.
- [24] DoĀru H, Yasan H, Özel BF, Baykal B. Difficulty in the diagnosis and management of parapharyngeal abscess: foreign body. *KBB-Forum* 2005; (4):192-194.
- [25] Shalaby HAA, Maaly M A, Abdella TF. Ultrasonography diagnostic validity in structural and functional laryngeal disorders. *Menoufia medical journal.* 2013; 26:170-176.