
Right Heart Thrombus in-Transit in Patient with Acute Pulmonary Embolism Treated by Thrombolytic Therapy with Tenecteplase

Warkaa Al Shamkhani, Nagham Saeed Jafar, Sunil Roy Narayanan*,
Krishna Ramanagaram Gowda, Anil Kumar Rajappan

Department of Cardiology, Belhoul Speciality Hospital, Dubai, UAE

Email address:

sunilroytn@hotmail.com (S. R. Narayanan)

To cite this article:

Warkaa Al Shamkhani, Nagham Saeed Jafar, Sunil Roy Narayanan, Krishna Ramanagaram Gowda, Anil Kumar Rajappan. Right Heart Thrombus in-Transit in Patient with Acute Pulmonary Embolism Treated by Thrombolytic Therapy with Tenecteplase. *International Journal of Medical Imaging*. Vol. 3, No. 2, 2015, pp. 11-15. doi: 10.11648/j.ijmi.20150302.11

Abstract: A thrombus in transit is an uncommon life threatening condition with high morbidity and mortality. Thrombectomy, thrombolytic therapy and anticoagulation are the treatment options in patients with acute pulmonary embolism and thrombus in transit. A 30-year old male presented with acute submassive pulmonary embolism. Echocardiography showed features of acute pulmonary embolism with right ventricular dysfunction and large fresh mobile thrombus in the right ventricular cavity. He was treated by thrombolytic therapy with Tenecteplase. He made an uneventful recovery with normalisation of the ECG, CXR and Echocardiography on subsequent follow up. This case demonstrates the efficacy of thrombolytic therapy in patients with right ventricular thrombus in transit.

Keywords: Thrombus in Transit, Thrombolytic Therapy, Pulmonary Embolism

1. Introduction

Acute Pulmonary embolism (PE) is a common and often fatal disease. In spite of improved methods in diagnosis and treatment of pulmonary embolism, the mortality is still estimated to be between 20 - 30%.¹ A thrombus that is lodged temporarily in right heart chambers on its way to pulmonary artery is called thrombus in transit.² It is an uncommon, but life threatening condition. In patients presenting with Acute Pulmonary embolism (PE), documentation of right heart thrombus in transit is associated with significantly higher mortality compared to those presenting with pulmonary embolism alone.³ Thrombolytic agents have been used to dissolve thrombus and improve circulation in patients with acute pulmonary embolism⁴ and they have shown to reduce mortality in patients with right heart thrombus compared with heparin alone. We present a case of PE in a 30 year-old-man who has documented thrombus in right ventricle treated by thrombolytic therapy.

2. Case Report

A 30-year-old man presented to the Emergency

Department (ED) with history of worsening breathlessness on exertion that prevents him from walking more than 20 meters. He has been experiencing shortness of breath and palpitation since one week. His past medical history was significant only for cerebral venous sinus thrombosis that happened 2 years ago and he made a complete recovery out of it. He has taken oral anticoagulation for 6 months and then discontinued. He does not smoke cigarette or drink alcohol. His family history was negative for both coronary artery disease and venous/arterial thrombosis. He denied any drug abuse and he was leading an active lifestyle till the symptoms started. He was investigated in a local hospital with ECG, 2-D echocardiography and Trans-esophageal echocardiography with right sided cardiac chamber enlargement. He was started on Ivabradine for his sinus tachycardia and discharged home. His symptoms got worse gradually till he was getting out of breath on walking even 20meters. When he was seen in ED, he looked in discomfort, pale, BP100/88mmgh, HR 125beat/min, RR 23 breath/min, SPO2 96%. His jugular venous pulsations were seen up to the mid neck; cardiovascular examinations demonstrate tachycardia, normal first heart sound, loud second heart sound with wide variable split and an S3 gallop. His chest was clear to

auscultation. His extremities were warm, normal pulses and clinically no signs of deep vein thrombosis.

Electrocardiogram done in the ED showed sinus tachycardia at a rate of 130 beat/min with S1, Q3, T3 pattern, [Figure 1] suggestive of acute pulmonary embolism. His arterial blood gas analysis showed pH of 7.452, pCO₂ 27 mm of Hg and pO₂ 69 mm of Hg on rebreathing oxygen mask. Bedside echocardiography showed dilatation of right atrium and ventricle with hypokinesia of right ventricular free wall and the ventricular septum, moderate pulmonary hypertension with pulmonary artery systolic pressure of 60 mm of Hg, moderate tricuspid regurgitation and normal left ventricular function and enlargement of both right ventricle (RV) and right atrium. It is also noted a fresh and freely mobile thrombus occupying the RV [Figure 2]. His chest X-ray showed dilatation in main pulmonary artery and its right branch with decrease vascularity in right lower zone [Figure 3]. His troponin I was elevated at 0.13 ng/ml [Normal <0.04ng/ml]. Complete blood count, basic metabolic panel and coagulation panel were normal. An urgent CT pulmonary angiography showed uniform filling defects in the right pulmonary artery (Figure 4) and its lower and middle lobe branches. Similar uniform filling defect was also noted within the left lower lobar pulmonary artery and its branches.

Due to the hypoxia, classical ECG and Echocardiographic findings of right ventricular strain and dysfunction, acute PE remained the most likely diagnosis. The patient was given

oxygen via facemask, intravenous fluid and subcutaneous low molecular weight heparin. His BP remained stable. Given the clinical finding of hypoxia gathered by the echo finding of elevated pulmonary artery pressure, the patient was given thrombolytic therapy with Tenecteplase IV of 7000 Units over 5 seconds. He was moved to the intensive care unit for monitoring. Although the condition stabilized initially, the patient developed worsening of breathlessness and hypoxia and tachycardia 2 hours after thrombolytic therapy. He was continued on anticoagulation with low molecular weight heparin, high flow O₂ via face mask was ensured to maintain saturation above 95%, His symptoms gradually improved over the next 12 hours. ECG on the next day showed normal sinus rhythm with disappearance of S1,Q3, T3 pattern (Figure 5) and CXR showed restoration of the vascularity of the right lower zone (Figure 6).

He was continued on anticoagulation with low molecular weight heparin and later overlapped with Warfarin. Venous Doppler study of both lower limbs did not show any deep vein thrombus. A hypercoagulable work-up later revealed that the patient suffers from protein S deficiency. His general condition continued to improve. He was started on Warfarin and discharged once the therapeutic INR was achieved. He is doing well on follow up. Repeat Echocardiography showed normalization of right atrial and right ventricular size and normalization of PA pressures. He is doing well after 6 months of follow up.

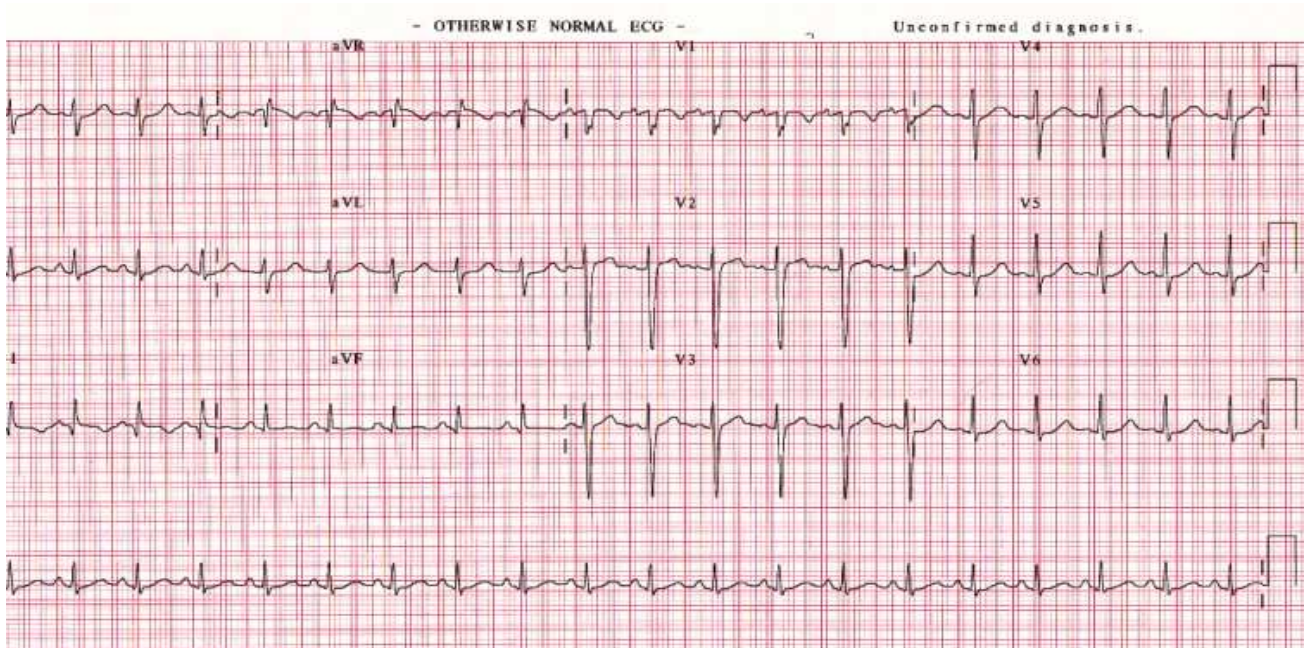


Figure 1. ECG at presentation showing sinus tachycardia, prominent S wave in lead I and small Q wave with inverted T wave in lead III (S₁, Q₃, T₃ pattern).

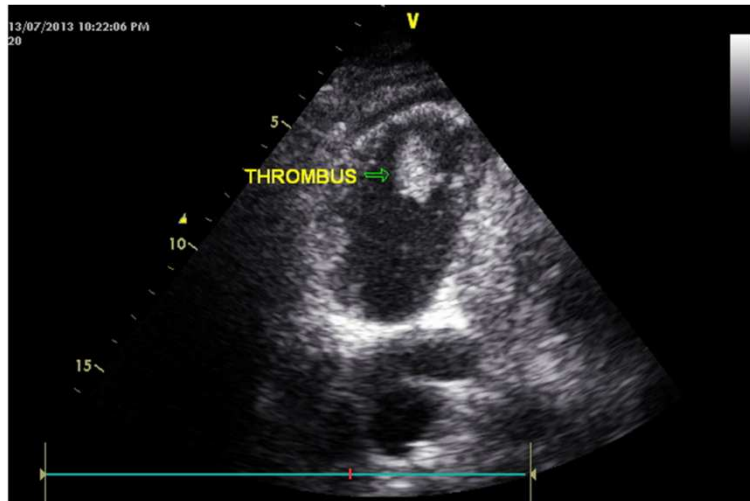


Figure 2. Trans-thoracic bedside echocardiography showing enlargement of right ventricle (RV) with fresh and freely mobile thrombus occupying the RV near the apex

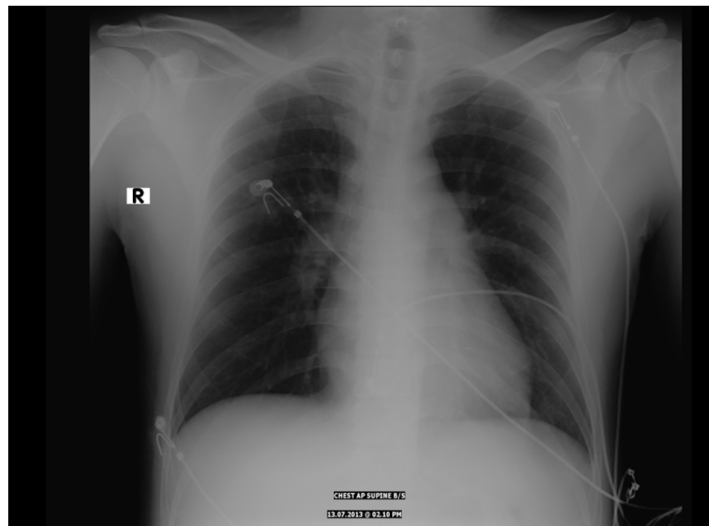


Figure 3. Chest radiograph showing abrupt cut-off of the right descending pulmonary artery with oligemia in the right lower zone of the right lung.

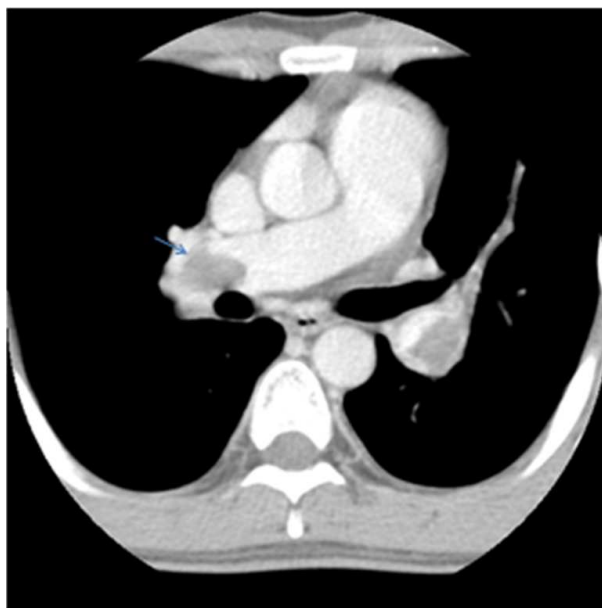

Figure 4. Axial Computed tomographic pulmonary angiogram illustrating large filling defect obstructing the right lower lobe pulmonary artery.

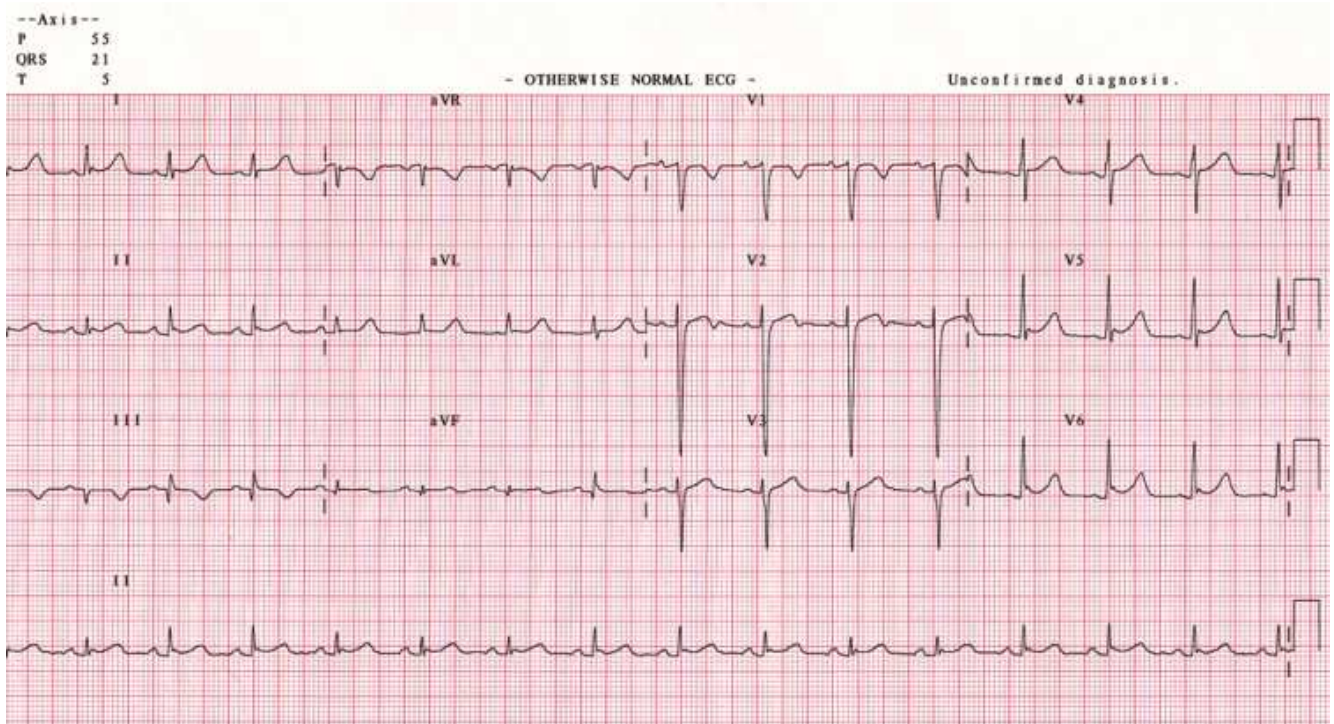


Figure 5. ECG shows resolution of the S wave in lead I and normalization of the heart rate 24 hours after thrombolytic therapy.

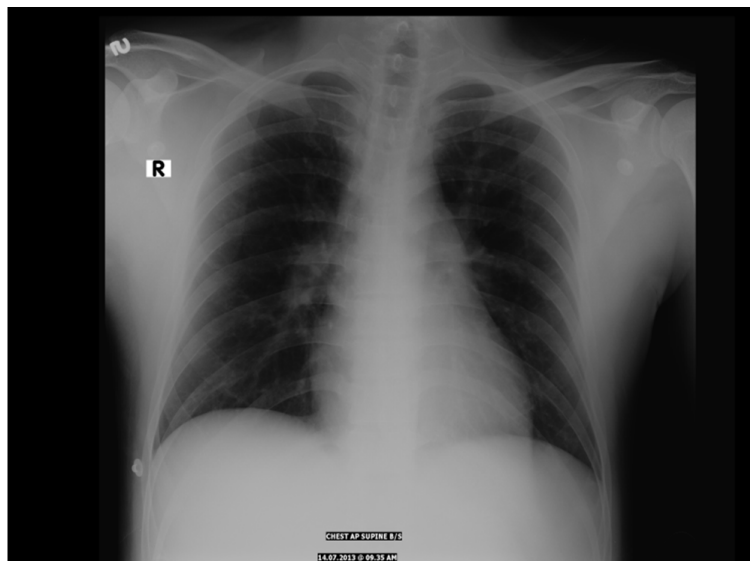


Figure 6. Chest X ray normalization of the pulmonary vasculature on the right side 24 hours after thrombolytic therapy.

3. Discussion

Pulmonary embolism still represents an under diagnosed health care problem. Despite improved methods in diagnosis and treatment of pulmonary embolism, the mortality is still estimated to be between 20 - 30%.¹ During its immediate course, pulmonary embolism may be fatal, with a cumulative three month mortality of 17.5 %.⁵ At least 4 registries have proved the role of thrombolytic therapy in the reduction of mortality due to submassive PE.

Thrombolytic agents have been used to dissolve thrombus and improve circulation in patients with acute pulmonary

embolism. The use of Tenecteplase as a thrombolytic agent in acute pulmonary embolism is increasing recently.⁶ It is being widely used as the treatment of this condition. There are several published case series in favor of its use in pulmonary embolism.^{7,8,9} Its feasibility for use in the emergency department with simple administration regime has made it an attractive alternative to the older thrombolytic agents which require more complex regime and dosing protocol. Most cases did not develop significant hemorrhage and had acceptable outcome.

Free floating right heart thrombi are seen in 18% of cases of acute massive pulmonary embolism. They are associated with higher mortality due to potential fragmentation and

recurrent pulmonary embolization. Echocardiography is well known to be the best non-invasive test to diagnose FRHT.¹⁰ The treatment of choice for thrombus-in-transit is not yet well defined. There are some case reports of disappearance of thrombus following thrombolytic therapy. In patients with right ventricular strain, thrombolytic therapy reduces the mortality by decreasing pulmonary vascular resistance and improvement in cardiac index. Surgical embolectomy¹¹ and percutaneous removal of thrombus by special wire mesh basket remain other treatment options.¹²

This patient represents one of the successful thrombolysis cases of PE with thrombus in transit using Tenecteplase. His ECG and right ventricle findings on Echocardiography were all reverted back to normal. The floating thrombus in the RV, proved the possibility of an existed DVT in one of the limbs, although Doppler lower limbs was normal, the fact that it was done only after the initiation of the treatment plus the detected free mobile thrombus in the right ventricle make the DVT more likely as a source of the pulmonary embolism. The successful thrombolysis of this patient with Tenecteplase confirms its usefulness in acute pulmonary embolism.

Our case report demonstrates the usefulness of Tenecteplase in the treatment of right heart thrombus in transit leading to pulmonary embolism. Its feasibility for use in the emergency department with simple administration regime makes it an attractive thrombolytic agent in patients with this condition. Bedside echocardiography is a simple investigation which can be carried out in the emergency room that can diagnose thrombus in transit and helps in the early institution of treatment.

Acknowledgment

The authors gratefully acknowledge Mr. Abdul Subhan Salahuddin for his assistance with figures and videos and Ms. Siya Jacob for her secretarial assistance

References

- [1] Task Force Report. Guideline on Diagnosis and Management of Acute Pulmonary Embolism. European Society of Cardiology. *Eur Heart J* 2000; 21:1301-36.
- [2] Redberg RF, Hecht SR, Berger M. Echocardiographic detection of transient right heart thrombus: now you see it, now you don't. *Am Heart J* 1991; 122: 862-4.
- [3] Chartier L, Bera J, Delomez M et al. Free- floating thrombi in the right heart: diagnosis, management, and prognostic indexes in 38 consecutive patients. *Circulation* 1999; 99: 2779-93.
- [4] Rose PS, Punjabi NM, Pearse DB. Treatment of right heart thromboemboli. *Chest* 2002; 121: 806-14.
- [5] Golhaber SZ, Visani L, De Rosa M. Acute Pulmonary Embolism: Clinical Outcomes in the International Cooperative Pulmonary Embolism Registry (ICOPER). *Lancet* 1999; 353:1386-9.
- [6] Livaditis IG, Paraschos M, Dimopoulos K. Massive pulmonary embolism with ST elevation in leads V1-V3 and successful thrombolysis with Tenecteplase *Heart* 2004; 90: e41.
- [7] Kline JA, Nordenholz KE, Courtney DM et al. Treatment of submassive pulmonary embolism with Tenecteplase or placebo: cardiopulmonary outcomes at 3 months: Multicenter double-blind, placebo controlled randomized trial. *J Thromb Haemost* 2014; 12: 459-68.
- [8] Patra S, Nagesh CM, Reddy B et al Thrombolysis with single bolus Tenecteplase compared with Streptokinase infusion in the treatment of acute pulmonary embolism: A pilot study. *Clin Appl Thromb Hemost* 2013.
- [9] Steering Committee. Single-bolus Tenecteplase plus heparin compared with heparin alone for normotensive patients with acute pulmonary embolism who have evidence of right ventricular dysfunction and myocardial injury: rationale and design of the Pulmonary Embolism Thrombolysis (PEITHO) trial. *Am Heart J* 2012; 163: 33-38.
- [10] Babu K, Krishnan MN, Vinayakumar D et al. A floating right heart thrombus in transit across tricuspid valve causing an endocardial friction rub. *Indian Heart J* 2013; 65: 457-9.
- [11] Hisatomi K, Yamada T, Onohara D. Surgical embolectomy of a floating right heart thrombus and acute massive pulmonary embolism: report of a case. *Ann Thorac Cardiovasc Surg* 2013; 19: 316-9.
- [12] Richartz BM, Werner GS, Ferrari M et al. Non-surgical extraction of right cardiac "thrombus in transit". *Catheter Cardiovasc Interv* 200; 51: 316-9.