
The importance of the mental foramen location detection by using different radiographic technique: Mini review

Mohammed Jasim Al-Juboori^{1, *}, Chua Miao Hua², Kuo Yuet Yuen²

¹Lecturer in oral surgery department/ Dental Faculty, MAHSA University, level 4, block E, pusat bandar damansara, Kuala Lumpur, Malaysia

²Dental Faculty, MAHSA University, level 4, block E, pusat bandar damansara, Kuala Lumpur, Malaysia

Email address:

doctor_mohamed_2006@yahoo.com (M. J. Al-Juboori)

To cite this article:

Mohammed Jasim Al-Juboori, Chua Miao Hua, Kuo Yuet Yuen. The Importance of the Mental Foramen Location Detection by Using Different Radiographic Technique: Mini Review. *International Journal of Medical Imaging*. Vol. 2, No. 3, 2014, pp. 63-68.

doi: 10.11648/j.ijmi.20140203.14

Abstract: This review gives detail information about the mental foramen location, shape, size and numbers and its variation between races. Studies have shown that there are variations in the position of mental foramen in different populations. It may lie between the apices of premolars, below the apex of first or second premolars. This variations mandate accurate detection of foramen during examination and treatment plan stage. Foramen detection usually done by 2 dimension radiograph, with high chances of error. Three dimension radiograph provide the operator more precise location and dimension of the foramen that decrease the chances of the mental nerve damaging during the surgery.

Keywords: Mental Foramen, Nerve Damage, Radiograph, Dental Implant, Oral Surgery

1. Introduction

Knowing the location of the mental foramen is very important when considering placing implants or any other surgical procedure in the foraminal region. The complications, such as altered sensation, numbness and pain can be avoided if the mental foramen is located and evaluated.¹ There are variations in the location, the number of foramina, and the possibility that an anterior loop may be present mesial to the mental foramen in different populations. This article reviews the literature with respect to the mental foramen and determines the safety zone prior to preparing an osteotomy for implant placement in this region.

2. Mental Foramen

2.1. Shape

According to Mbajjorgu et al.², there are different shapes of the mental foramen be found in the mandibles of Zimbabwean subjects: round in 14 of 32 mandibles (43.8%) and oval in 18 of 32 jaws (56.3%). Meanwhile, Grershenson A. et al.³ reported that it was round in 34.5% of mandibles and oval in 65.5%.

2.2. Size

Neiva et al.⁴ stated that the morphometric skull analyses revealed the mean height of the mental foramen was 3.47mm (range: 2.5 to 5.5 mm) and the average width was 3.59mm (range: 2 to 5.5 mm). Others reported that the mean diameter of the foramen was 3.5mm⁵ and 5mm wide.⁶

2.2.1. Location

According to textbooks of anatomy, the mental foramen is located below the interval between the premolar, or the second premolar, from which emerge the mental nerve and vessels.³⁴ However, there are anatomical variations concerning the mental foramen's location.^{7, 8} It is usually found more coronal than the mandibular canal.^{9, 10} Neiva et al.⁴ reported the foramen was 27.6mm (range: 22 to 31 mm) from the midline and 12mm (range: 9 to 15mm) from the most apical portion of the lower cortex of the mandible. Meanwhile, Agthong et al.¹¹ stated that the foramen was 28 mm from the midline of the mandible and 14 to 15 mm from the inferior border of the mandible. Other investigators noted that the foramen was usually found halfway between the crest of bone and the inferior border of the mandible.¹²

Table 1^{4, 10, 13-16, 27-32} lists studies that addressed the mental foramen's location in the horizontal plane. Usually, it is

located by the apex of the second mandibular premolar or between the apices of the premolars. However, there are some minor differences among the races. For example, Wang *et al.*¹³ stated that the mental foramen in the Chinese population is usually located apical to the second premolar,

whereas in Caucasian subjects, according to Fishel *et al.*¹⁰ and Neiva *et al.*⁴, it is usually found between the premolars. Atypically, it can be found anteriorly by the canine or posteriorly by the first molar.^{14-16, 27, 29, 31-32}

Table 1. Locations of mental foramen that detected from different study in different races and techniques

Study	Population	N	Horizontal Plane			Vertical Plane
			Apical to second premolar	Between apices of premolars	Other locations	
Fishel <i>et al.</i> (1976) ¹⁰	Caucasian	1000	18.9	70.4	Apex first premolar: 3.3 Mesial to first premolar: 1.5 Between premolar/molar: 6.6 By the molar: 1	Superior to the level of the apices of the premolars
Wang <i>et al.</i> (1986) ¹³	Chinese	100	59	21	Between premolars/ molars: 19 By the molar: 1	Distance between superior border of the MF and the bottom of the lower second premolar socket: 2.50 mm
Kekere – Ekun (1989) ¹⁵	Nigerian	604	55.63	26.99	Mesial to first premolar: 0.17 Apex first premolar: 1.66 Between premolar/ molars: 12.3 By the molar: 3.3	Not measured
Shankland (1994) ²⁷	Asian Indians	138	75.4	5.8	Between premolar/ molars: 14.5 By the molar: 4.3	Not measured
Al Jasser and Nwoku (1998) ²⁸	Saudi	414	45.3	42.7	Not measured	Not measured
Ngeow and Yuzawati (2003) ¹⁴	Malay	169	69.2	19.6	Apex first premolar: 3.4 Between premolar/ molar: 6.6 By the molar: 1	Not measured
Neiva <i>et al.</i> (2004) ⁴	Caucasian	22	42	58	Not measured	Distance between MF and CEJ of teeth: 15.52 +/- 2.37 mm
Apinhasmit <i>et al.</i> (2006) ²⁹	Thai	106	56.9	28.7	Between premolar/ molar: 10.2 Apex first premolar: 3 By the molar: 1.2	Not measured
Kim <i>et al.</i> (2006) ³⁰	Korean	72	64.3	26.8	Apex first premolar: 8.9	Distance between the cusp tip and the superior border of the mental foramen: 23.42 mm
Fabian (2007) ³¹	Tanzanian	100	45	12	Between premolar/ molar: 35 By the molar: 8	Not measured
Haghanifar and Rokouei (2009) ³²	Iranian	400	46	47.2	Between premolar/molar: 5.3 By the molar: 1.5	Not measured

Fishel *et al.*¹⁰ (N= 936 full-mouth series) commented that the mental foramen's location in the vertical plane (occluso-apically) for the first and second premolars: 38.6% coronal to the apex of the first premolars, 15.4% at the apex of the first premolars, and 46.0% apical to the apex of the first premolars; whereas for the second bicuspid, 24.5% coronal to the apex, 13.9% at the apex, and 61.6% apical to the apex. It can be concluded that the foramen's location is not constant in the horizontal or vertical planes.¹

It can be seen that the mental foramen is closer to the alveolar crest after the extraction of teeth and resorption of alveolar bone. In some extreme situations, the mental foramen and mandibular canal can be adjacent to the crest of

the alveolar ridge. Hence, using alveolar crest bone as a landmark is not stable because different levels of crestal bone loss existed.

2.2.2. Number of Foramina

There may be more than one mental foramen present.^{7, 8} Sawyer *et al.*⁸ assessed the frequency of accessory mental foramina in skulls in 4 population groups: American Whites = 1.4%; Asian Indians = 1.5%; African Americans = 5.7%; and pre-Columbian Nazca Indians = 9.0%. Some studies found that there were two mental foramina in 1.8% (N = 110) of examined Asian skulls¹¹ and in 10% (N = 50) of examined cadavers.³³ In contrast, de Freitas *et al.*²⁴ found no mental foramen in some skulls (among 1,435 dry human mandibles,

the foramen was absent twice on the right side [0.06%] and once on the left side [0.03%]). It can be concluded that there is a variety of patterns occurs, and it should not be assumed that there is only one mental foramen on each side.¹

2.2.3. Path of Emergence of Mental Foramen

According to Solar et al.⁶, the mental canal (the anterior opening of the mandibular canal) traverses cranially at an angle of inclination ranging from 11° to 77°. The average gradient was 50° in 37 specimens and 22 had an anterior loop. Kieser et al.²⁵ classified the path of emergence of mental foramen into posterior, anterior, right-angled or multiple. They investigated the path of emergence of the mental canal in 117 Negro skulls (53 males), 114 Caucasoid skulls (62 males) and 100 pre-contact Maori skulls (70 males). Among all the Caucasoid and Maori skulls, the most common pattern of emergence was a posterior direction (86.7% of Caucasoid males, 90.2 % of Caucasoid females; 85.5 % of Maori males, and 93.1 % of Maori females). While for the Black population, the most common pattern of path of emergence was the right-angled one, which was 45.8% of males, 45.0% of females. In Fabian's study on measurements of 100 Tanzanian mandibles³¹, he concluded that the direction of mental foramen opening was superiorly in 44%, posterosuperiorly in 40%, labially in 10%; mesially (anteriorly) in 3%), and posteriorly in 3% of cases. (Figure 1). To create multileveled equations, it may be necessary to treat the equation as a graphic and insert it into the text after your paper is styled.

3. Detection of Mental Foramen on Radiograph

The ideal imaging technique for dental implant care should have several important characteristics such as, the ability to visualize the implant site in the mesiodistal, faciolingual and superioinferior dimensions; the ability to allow reliable, accurate measurements; a capacity to evaluate trabecular bone density and cortical thickness; a capacity to correlate the imaged site with the clinical site; reasonable access and cost to the patient; and minimal radiation risk.

The radiographic techniques that can be used to access the location of mental foramen are panoramic radiography, intraoral radiography, cephalometric radiography, conventional tomography as well as cone-beam and multidetector computed tomography.³⁵

3.1. Panoramic Radiography

Philips et al. found mental foramen on 75% (N=75) of periapical films⁴⁰, whereas Fishel et al. found mental foramen on 46.8% (N=1000) of periapical films in their study.¹⁰ In order to enhance the detection of foramen, it was suggested that a vertical bitewing and a panoramic film be taken in conjunction with a horizontal periapical film.⁴² Ngeow WC also suggested that 2 periapical radiographs

should be obtained at different angles (parallax technique), to ascertain the exact relationship of the premolars to the mental foramen.⁴³ Al-juboori et al⁴⁴, conduct a study among Malaysian population to detect the mental foramen location by using panoramic radiograph, the study shows the feasibility of using panoramic radiograph in detection the location of the mental foramen among different races.

3.2. Digital Radiography

Digital radiography has more advantages than conventional plain film radiography, including speed, convenience, lack of darkroom procedures, computer image improvement, less environmental contamination and better patient education. It also imposes lower radiation exposure dose to the patient^{45,46}. Studies have found that digital radiography has a 50-80% decrease in exposure dose compared with conventional plain film imaging.

However, on average, the total amount of decrease in exposure dose is 25%, as clinicians tend to repeat more radiographs when using the digital radiograph^{47,48}. Parissis et al, also found that digitized radiographs has higher density than the conventional radiographs, moreover, they demonstrated a narrower density range. The resolution between the digitized image and the film-based radiographs has found to be the same.⁴⁵

3.3. Computed Tomography (CT)

Computed tomogram enables the mandible to be visualized in three dimensions.⁴⁹⁻⁵⁵ The mandibular canal and its surrounding bone can be appreciated in three dimensions. By using computed tomogram, the clinicians will be able to know the bone density, buccolingual position of the mandibular canal, height of the bone.⁴⁹⁻⁵⁸ The accuracy of computed tomography was within 0.5mm of the caliper measurement in every reading taken. There was no distortion of the computerized tomographic measurements in eight out of the twelve readings. According to Sonick et al⁵⁹, the following average linear errors occurred during routine bone assessment (N=12): panoramic films: 24% (mean: 3mm; range: 0.5-7.5mm); periapical films: 14% (mean: 1.9mm; range: 0.0 to 5.0mm); and computerized tomography scans: 1.8% (mean: 0.2mm; range: 0.0 to 0.5mm).⁵⁹

4. Mental Nerve Damage Due to Miss Diagnosed Mental Foramen during Dental Implant Treatment

According to Sharawy et al., nerve damage can result from the nerve being stretched, compressed, and partially or totally transected.⁶⁰ Parasthesia (numb feeling), hypoesthesia (reduced feeling), hyperesthesia (increased sensitivity), dyesthesia (painful sensation), or anesthesia (complete loss of feeling) of the teeth, the lower lip, or surrounding skin and mucosa may be encountered during an

osteotomy.⁶⁰ It is not surprising that venous or arterial bleeding can also occur. Other terms used to describe nerve injuries are:⁶¹

Neurapraxia: The nerve has been stretched or undergone blunt trauma. No loss of continuity of the nerve occurs. The paresthesia will subside and feelings will be returned in days to weeks.

Axonotmesis: There is nerve damage, but the damage is not severe. Feelings will be returned within 2 to 6 months.

Neurotmesis: There is severe nerve damage. It is a poor prognosis for resolution of paresthesia.

Reasons like osteotomy locations, manner of surgery, study design, sensitivity of assessment techniques, selection of outcome variables, and terminology employed to explain sensory disturbances determine the prevalence of sensory alterations.⁶² Walton⁶³ reported that 1% of the patients experienced sensory alterations 1 year after therapy, whereas Bartling *et al.*⁶⁴ noted no permanent alterations of sensation 4 months post therapy (N= 94). Some investigators found transient altered lip sensations after implant placement in the anterior mandible: 8.5% (N=94)⁶⁴, 11% (N = 110)⁴¹, and 24% (N=75) of patients.⁶³ In another study, 7% (N= 110) of the patients noted sensory disturbance 16 months after the treatment.⁴¹ Although the mental foramen was exposed as part of the surgical procedure and placement of implants at least 3mm in front of the mental foramen, this incident still occurred. Due to these issues, patients must be forewarned of these possible complications prior to implant surgery. Besides, Flanagan³⁷ reported that there was delayed onset of altered sensation of the mental nerve after surgery. According to him, it might be due to the remote bone compression which causing his patients to experience transient altered sensation. It was not due to the direct injury induced by the twist drill. Flanagan³⁷ believed that the implant, which compresses the cancellous bone may in turn presses on the nerve, resulting in nerve dysfunction. Bone compression occurs because the implant used is usually 0.5mm wider than the osteotomy, and because of this, the force may be transferred to the nerve.

Table 2. Appearance of mental foramina on panoramic radiographs: Percentage of occurrence from Yosue *et al* study³⁸

Category	Radiographic Appearance	Incidence (N=297)
Continuous	Foramen has continuity with the mandibular canal	21%
Separated	Foramen distinctly separated from the canal	43%
Diffuse	Foramen has indistinct border	24%
Unidentified	Foramen cannot be identified	12%

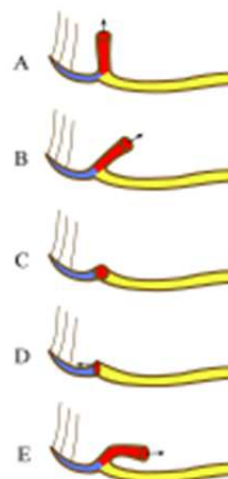


Figure 1. Emergence patterns of the mental canal and mental foramen opening. Colours: blue = mandibular incisive canal, red = mental canal 9th anterior opening of the mandibular canal, yellow = mandibular canal, A = superiorly, B = posterosuperiorly, C = labially, D = mesially (anteriorly), E = posteriorly

5. Conclusion

From this mini review we can conclude that 3 dimensional imaging which is presented by computerized tomography is mandatory when dental implant or oral surgical procedure conducted in the mental foramen area, this will prevent neural complication and patient morbidity

Acknowledgements

Acknowledge goes to Mr. Mohammed Zaki Noor Al-Hashimi/ biostatistics lecturer in MAHSA University, for his great support and effort

References

- [1] Gary Greenstein and Dennis Tarnow. The mental foramen and nerve: Clinical and anatomical factors related to dental Implant Placement: A Literature Review. *Journal of Periodontology* 2006; 77: 1933-1943
- [2] Mbajiorgu EF, Mawera G, Asala SA, *et al.* Position of the mental foramen in adult black Zimbabwean mandibles: A clinical anatomical study. *Cent Afr J Med* 1998; 44: 24-30
- [3] Gershenson A, Nathan H, Luchansky E. Mental foramen and mental nerve: Changes with age. *Acta Anat (Basel)* 1986; 126:21-28.
- [4] Neive RF, Gapski R, Wang HL. Morphometric analysis of implant-related anatomy in Caucasian skulls. *J periodontal* 2004; 75:1061-1067.
- [5] Yosue T, Brooks SL. The appearance of mental foramina on panoramic radiographs. I. Evaluation of patients. *Oral Surg Oral Med Oral Pathol* 1989; 68:360-364.
- [6] Solar P, Ulm C, Frey G, *et al.* A classification of intraosseous paths of the mental nerve. *Int J Oral Maxillofac Implants* 1994; 9:339-344.

- [7] Shankland WE. The position of the mental foramen in Asian Indians. *J Oral Implantol* 1994; 20:118-123.
- [8] Sawyer DR, Kiely ML, Pyle MA. The frequency of accessory mental foramina in four ethnic groups. *Arch Oral Biol* 1998; 43: 417-420.
- [9] Bavitz JB, Harn SD, Hansen CA, Lang M. An anatomical study of mental neurovascular bundle-implant relationships. *Int J Oral Maxillofac Implants* 1993; 8: 563-567.
- [10] Fishel D, Buchner A, Hershkowitz A, et al. Roentgenologic study of the mental foramen. *Oral Surg Oral Med Oral Pathol* 1976; 41: 682-686.
- [11] Agthong S, Huanmanop T, Chentanex V. Anatomical variations of the supraorbital, infraorbital, and mental foramina related to gender and side. *J Oral Maxillofac Surg* 2005; 63: 800-804.
- [12] Mraiwa N, Jacobs R, van Steenberghe D, et al. Clinical assessment and surgical implications of anatomic challenges in the anterior mandible. *Clin Implant Dent Relat Res* 2003; 5: 219-225.
- [13] Wang TM, Shih C, Liu JC, et al. A clinical and anatomical study of the location of the mental foramen in adult Chinese mandibles. *Acta Anat (Basel)* 1986; 126: 29-33.
- [14] Ngeow WC, Yuzawati Y. The location of the mental foramen in a selected Malay population. *J Oral Sci* 2003; 45: 171-175.
- [15] Kekere-Ekun TA. Antero-posterior location of the mental foramen in Nigerians. *Afr Dent J* 1989; 3: 2-8.
- [16] Bergman RA, Afifi AK, Miyauchi R. mental foramen. In: *Illustrated Encyclopedia of Human Anatomic Variation: Opus V: Skeletal Systems*. Available at: <http://www.anatomyatlases.org/AnatomicVariants/SkeletalSystem/Images/127.shtml>. Accessed June 21, 2006.
- [17] Ulm CW, Solar P, Blahout R, et al. Location of the mandibular canal within the atrophic mandible. *Br J Oral Maxillofac Surg* 1993; 31: 370-375.
- [18] Block MS. *Color Atlas of Dental Implant Surgery*. Philadelphia: W.B. Saunders; 2001; 9.
- [19] Morrison A, Chiarot M, Kirby S. Mental nerve function after inferior alveolar nerve transposition for placement of dental implants. *J Can Dent Assoc* 2002; 68: 46-50.
- [20] Babbush CA. Transpositioning and repositioning the inferior alveolar and mental nerves in conjunction with endosteal implant reconstruction. *Periodontol* 2000; 17: 183-190.
- [21] Hori M, Sato T, Kaneko K, et al. Neurosensory function and implant survival rate following implant placement with nerve transpositioning: A case study. *J Oral Sci* 2001; 43: 139-144.
- [22] Nocini PF, De Santis D, Fracasso E, et al. Clinical and electrophysiological assessment of inferior alveolar nerve function after lateral nerve transposition. *Clin Oral Implants Res* 1999; 10: 120-130.
- [23] Ellies LG, Smiler DG, Quadland MW, et al. Inferior alveolar nerve repositioning: Is there cause for concern? *Dent Implantol Update* 1995; 6: 37-39.
- [24] De Freitas V, Madeira MC, Toledo Filho JL, et al. Absence of the mental foramen in dry human mandibles. *Acta Anat (Basel)* 1979; 104: 3533-355.
- [25] Kieser J, Kuzmanovic D, Payne A, et al. Patterns of emergence of the human mental nerve. *Arch Oral Biol* 2002; 51:14-16.
- [26] Oguz O, Bozkir MG. Evaluation of location of mandibular and mental foramina in dry, young, adult human male, dentulous mandibles. *West Indian Med J* 2002; 51: 14-16.
- [27] Shankland WE. The position of the mental foramen in Asian Indians. *J Oral Implantol*, 1994; 20: 118-123.
- [28] Al-Jasser, Nwoku AL. Radiographic study of the mental foramen in a selected Saudi population. *Dentomaxillofac Radiol.*, 1998; 27: 341-343.
- [29] Apinhasmit W, Chompoopong S, Methathathip D, et al. Supraorbital Notch/Foramen, Infraorbital Foramen and Mental Foramen in Thais: anthropometric measurements and surgical relevance. *J Med Assoc Thai.*, 2006; 89: 675-682
- [30] Kim IS, Kim SG, Kim YK, et al. Position of the mental foramen in a Korean population: a clinical and radiographic study. *Implant Dent*. 2006 ;15:404-11
- [31] Fabian FM. Position, shape and direction of opening of the mental foramen in dry mandibles of Tanzanian adult black males. *Ital J Anat Embryol*. 2007; 112:169-77
- [32] Sina HaghaniFar, Mehrak Rokouei Radiographic evaluation of the mental foramen in a selected Iranian population. *Indian J Dent Res*, 2009; 20,
- [33] Mraiwa N, Jacobs R, Moerman P, et al. Presence and course of the incisive canal in the human mandibular interforaminal region: Two-dimensional imaging versus anatomical observations. *Surg Radiol Anat* 2003; 25: 416-423.
- [34] Williams PL, Warwick R, Dyson M, banister LH *Grays Anatomy*. 37th ed. Churchill Livingstone, London, UK, 1989; pp. 367
- [35] Stuart C. White, Michael J. Pharoah. *Oral radiology: Principles and Interpretation*. 6th ed. Mosby, 2009; pp597.
- [36] Jacobs R, Mraiwa N, Van Steenberghe D, et al, Quirynen M. Appearance of the mandibular incisive canal on panoramic radiographs. *Surg Radiol Anat* 2004;26:329-333.
- [37] Flanagan d. Delayed onset of altered sensation following dental implant placement and mental block local anesthesia: A case report. *Implant Dent* 2002; 11:324-330
- [38] Yosue T, Brooks SL. The appearance of mental foramina on panoramic and periapical radiographs. II. Experimental evaluation. *Oral Surg Oral Med Oral Pathol* 1989; 68:488-92.
- [39] Dharmar S. Locating the mandibular canal in panoramic radiographs. *Int J Oral Maxillofac Implants* 1997;12:113-117
- [40] Phillips JL, Weller RN, Kulild JC. The mental foramen: 1. Size, orientation, and positional relationship to the mandibular second premolar. *J Endod* 1990; 16:221-223.
- [41] Wismeijer D, van Waas MA, Vermeeren JI, et al. Patients' perception of sensory disturbances of the mental nerve before and after implant surgery: A prospective study of 110 patients. *Br J Oral Maxillofac Surg* 1997; 35: 254-259
- [42] Moiseiwitsch JR. Avoiding the mental foramen during periapical surgery. *J Endod* 1995; 21:340-342.

- [43] Ngeow WC. Is there a "safety zone" in the mandibular premolar region where damage to the mental nerve can be avoided if periapical extrusion occurs? *J Can Dent Assoc* 2010; 76: a61.
- [44] Al-Juboori MJ, Al-Wakeel HA, Yun CM, et al. Location of mental foramen among Malaysia populations: Retrospective study by using orthopantomogram. *World J. Med. Med. Sci. Res* 2013; 1:85-90
- [45] Parissis N, kondylidou-Sidira A, Tsirlis A, et al. Conventional radiographs vs digitized radiographs: image quality assessment. *Dentomaxillofac Radiol* 2005; 34: 353-6.
- [46] Molander B, Grondahl HG, Ekestubbe A. Quality of film-based and digital panoramic radiography. *Dentomaxillofac Radiol* 2004; 33: 32-36.
- [47] Gijbels F, Jacobs R, Bogaerts R, et al, Dosimetry of digital panoramic imaging. Part I: patient exposure. *Dentomaxillofac Radiol* 2005; 34: 145-149.
- [48] Berkhout WER, Sanderink GCH, Van der Stelt PF. Does digital radiography increase the number of intraoral radiographs? A questionnaire study of Dutch dental practices. *Dentomaxillofac Radiol* 2003; 32: 124-127.
- [49] Schwarz MS, Rothman SLG, Rhodes ML, et al. Computerized tomography: Part I. Preoperative assessment of the mandible for endosseous implants surgery. *Int J Oral Maxillofac Implants* 1987; 2:137-141.
- [50] Rothman SLG, Chafetz N, Rhodes ML, Schwarz MS. CT in the preoperative assessment of the mandible and maxilla for endosseous implant surgery. *Radiology* 1988; 168:171-175.
- [51] McGivney GP, Haughton V, Strandt JA, et al. A comparison of computer-assisted tomography and data-gathering modalities in prosthodontics. *Int J Oral Maxillofac Implants* 1986; 1:55-68.
- [52] Schwarz MS, Rothman SLG, Chafetz N, et al. Computed tomography in dental implantation surgery. *Dent Clin N Am* 1989; 33:555-597.
- [53] Wishan MS, Bahat O, Krane M. Computed tomography as an adjunct in dental implant surgery. *Int J Periodont Rest Dent* .1988; 8:30-47.
- [54] Abrahams JJ, Levine B. Expanded application of DentaScan (multiplanar computerized tomography of the mandible and maxilla). *Int J Periodont Rest Dent* 1990; 10:465-471.
- [55] Abrahams JJ. CT Assessment of dental implant planning. *Oral Maxillofac Surg Clin N Am* 1992; 4:1-18.
- [56] Jaffin RA, Berman CL. The excessive loss of Brånemark fixtures in type IV bone: A 5 year analysis. *J Periodontol* 1991; 62:2-4.
- [57] Lekholm U, Zarb GA. Patient selection and preparation. In: Brånemark P-I, Zarb G, Albrektsson T (eds). *Tissue-Integrated Prostheses: Osseointegration in Clinical Dentistry*. Chicago: Quintessence 1985:202-208.
- [58] van Steenberghe D. Periodontal aspects of osseointegrated oral implants ad modum Brånemark. *Dent Clin North Am* 1988; 32:355-370.
- [59] Sonick M, Abrahams J, Faiella RA. A comparison of the accuracy of periapical, panoramic, and computerized tomographic radiographs in locating the mandibular canal. *Int J Oral Maxillofac Implants* 1994; 9: 455-460.
- [60] Sharawy M, Misch CE. Anatomy for dental implants In: Misch CE, ed. *Contemporary Implant Dentistry*, 2nd ed. St. Louis: The CV Mosby Company; 1999: 217-224
- [61] Jalbout Z, Tabourian G. *Glossary of Implant Dentistry*, Upper Montclair, NJ: International Congress of Oral Implantologists; 2004: 16
- [62] Dao TT, Mellor A. Sensory disturbances associated with implant surgery. *Int J Prosthodont* 1998; 11: 462-469
- [63] Walton JN. Altered sensation associated with implants in the anterior mandible: A prospective study. *J Prosthet Dent* 2000; 83:443-449
- [64] Bartling R, Freeman K, Kraut RA. The incidence of altered sensation of the mental nerve after mandibular implant placement. *J Oral Maxillofac Surg* 1999; 57: 1408-1412.